Ultrashort and Zero Echo Time MRI

Peder E. Z. Larson, Ph.D.

Surbeck Laboratory of Advanced Imaging, Department of Radiology and Biomedical Imaging, University of California, San Francisco, CA, United States

peder.larson@ucsf.edu

UCSF

University of California
San Francisco

Semi-solid Tissues

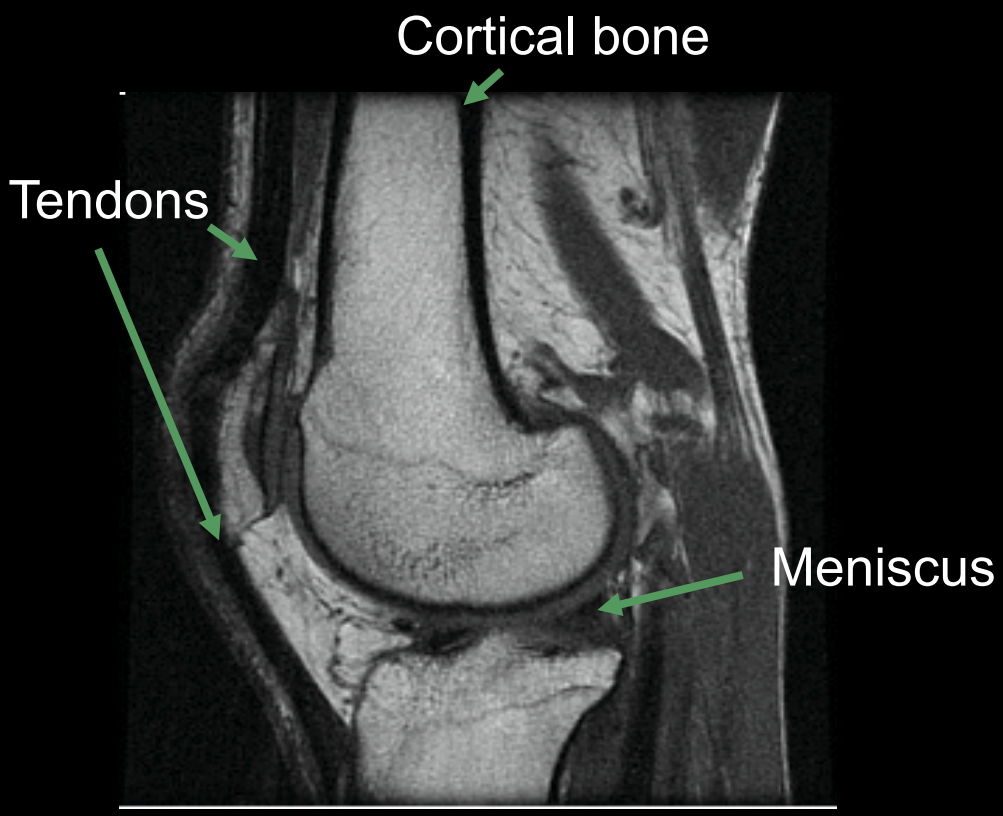

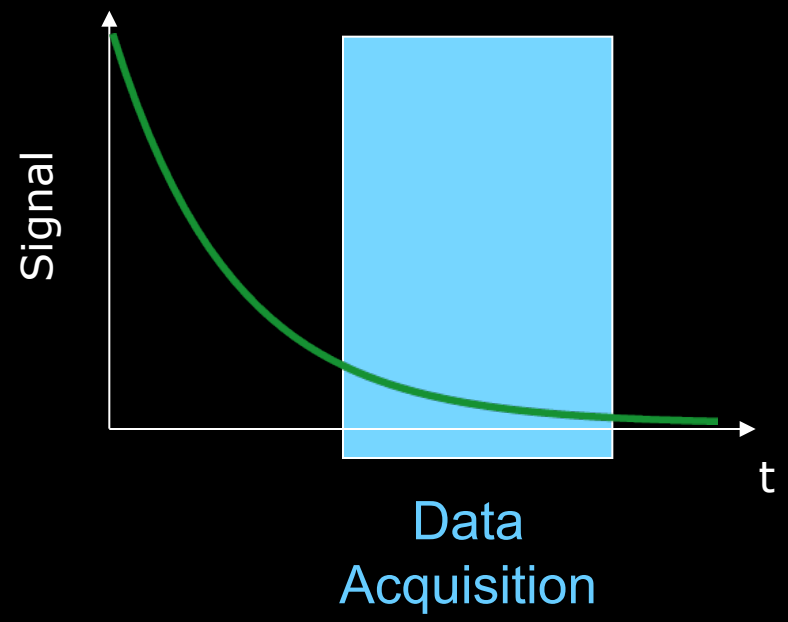

Examples:
Cortical Bone
Tendons
Lung Tissue
Myelin

Ultra-short/Zero Echo Time Imaging

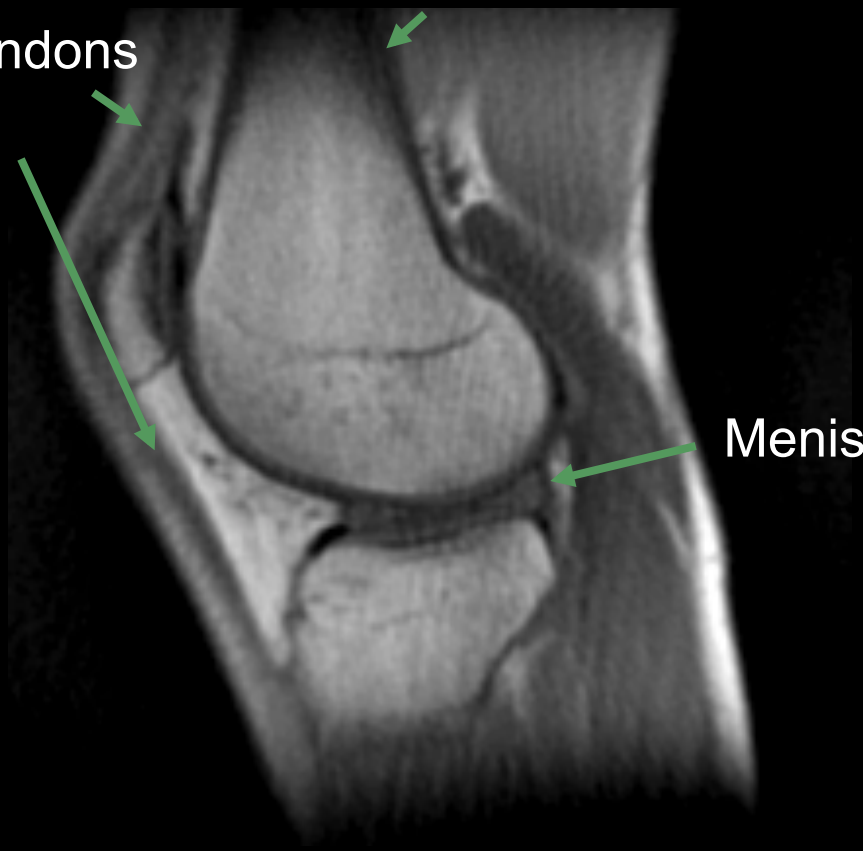

Potential Clinical Applications:
Bone mapping
Tendinopathy
Cancerous Lung Nodules
Fibrotic Lung Disease
Demyelination/dysmyelination

Dipole Field

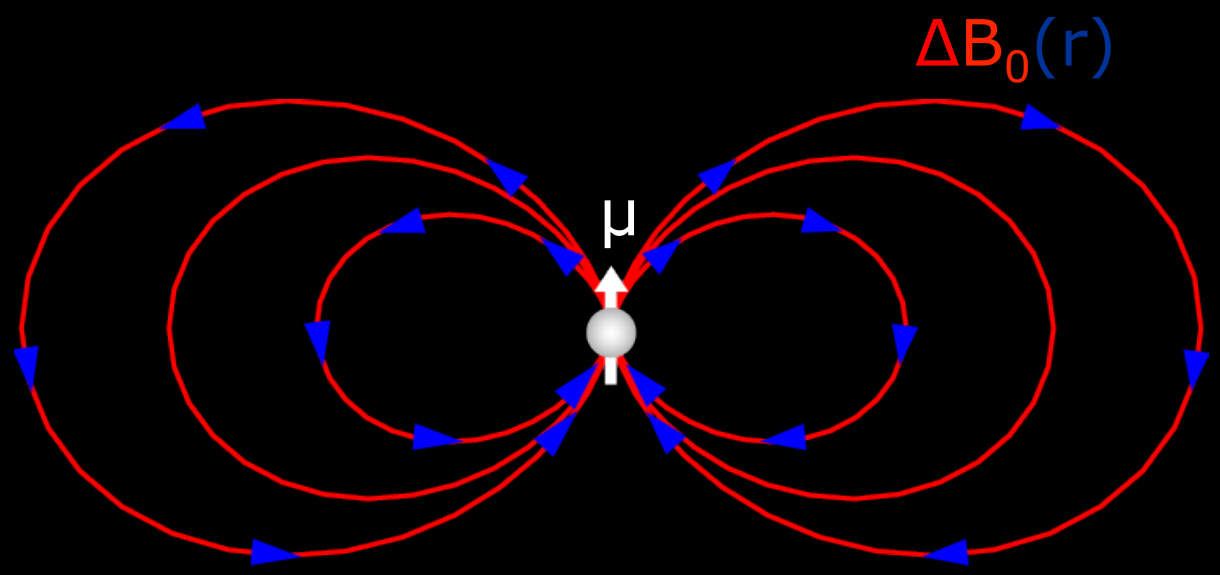

Magnetic dipole produces local (~nm) magnetic field variations, ΔB_0

Dipolar Coupling

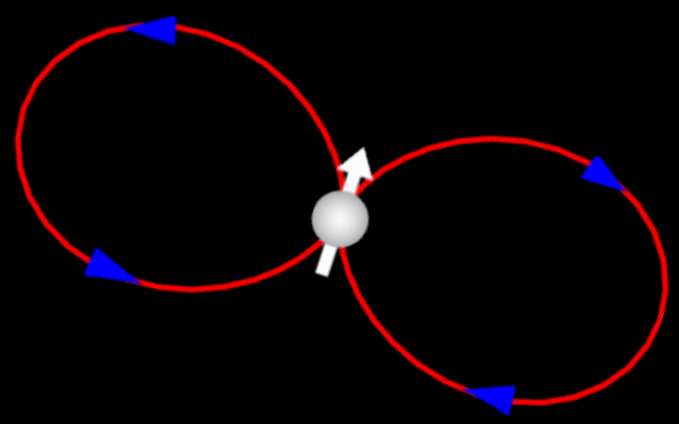

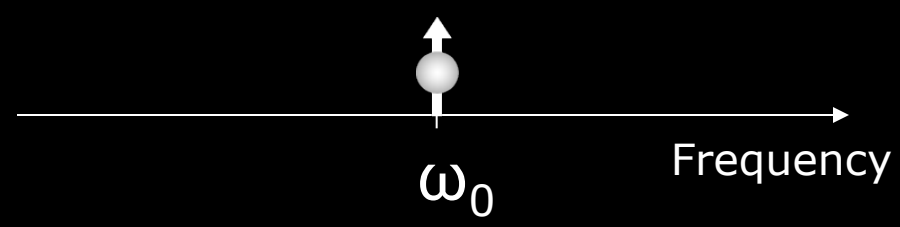

Dipolar Coupling

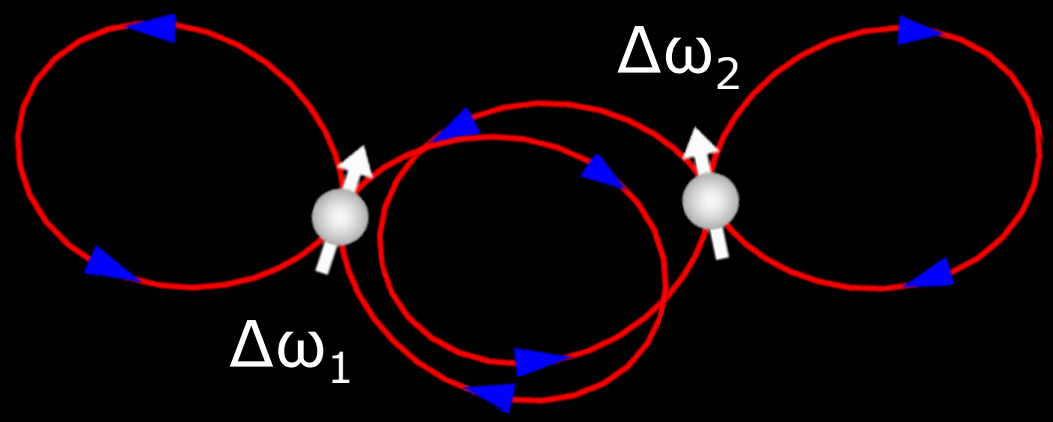

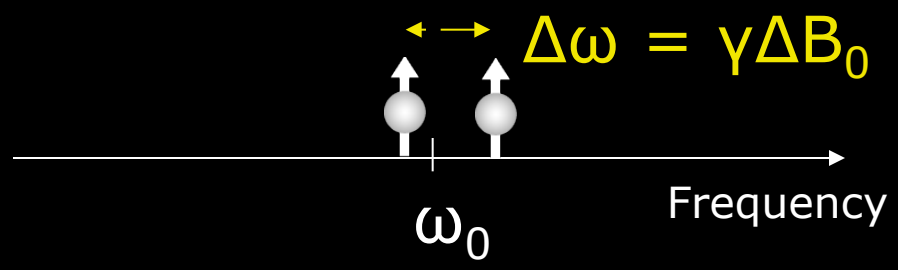

Dipoles couple, which induces resonance frequency shifts, $\Delta\omega$

Dipolar Coupling

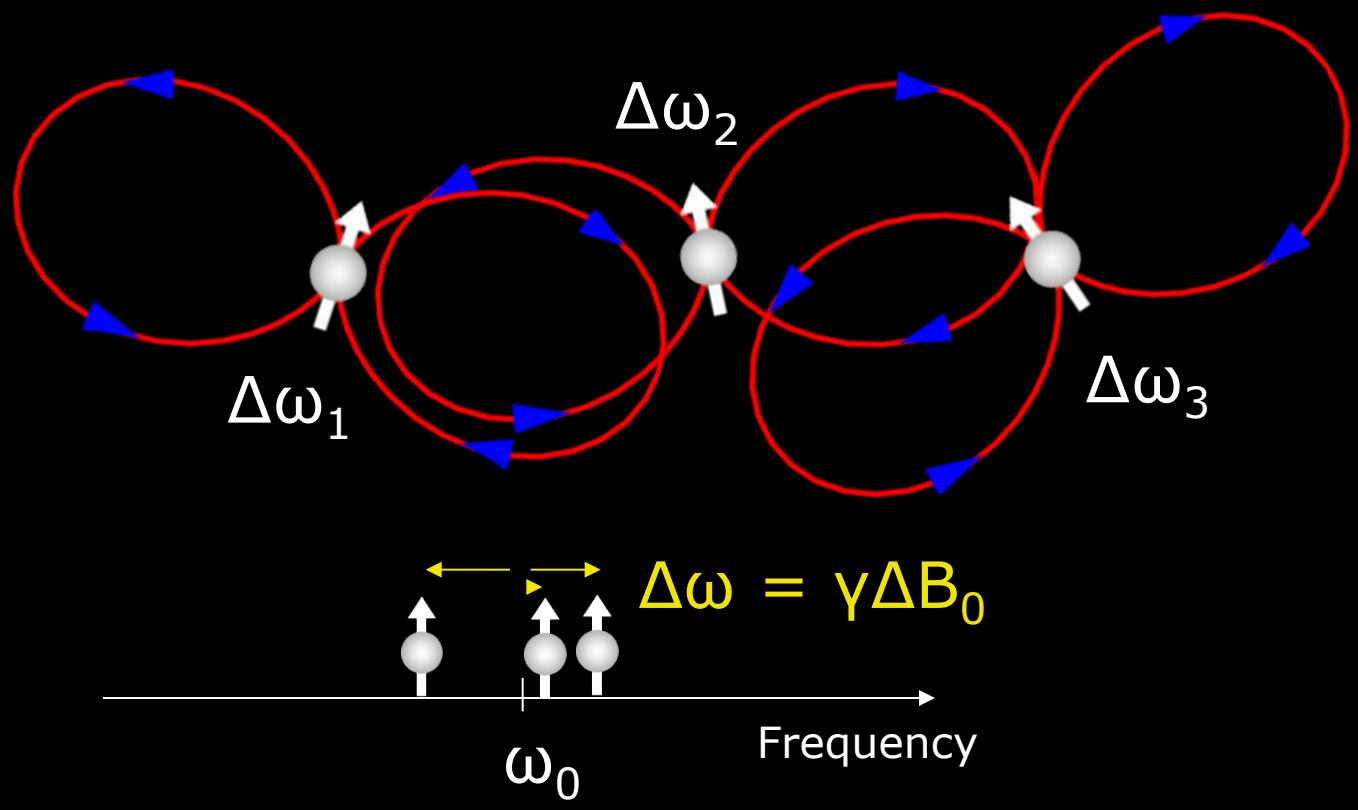

Dipoles couple, which induces resonance frequency shifts, $\Delta\omega$

Precession

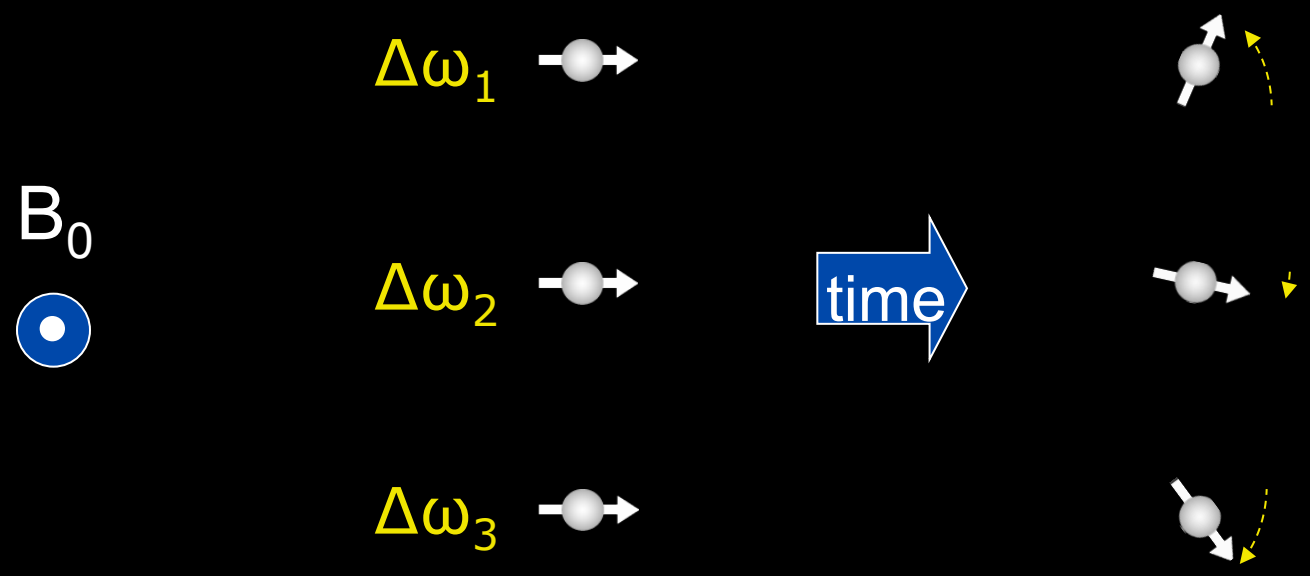

Spins precess around B_0 at their resonance frequency, ω

Rotating Frame: Demodulate precession at Larmor frequency $\omega_0 = \gamma B_0$

- "on-resonance" – $\omega = \omega_0$, acquires no phase
- "off-resonance" – $\omega = \omega_0 + \Delta\omega$, dephases from resonant spins

Dephasing

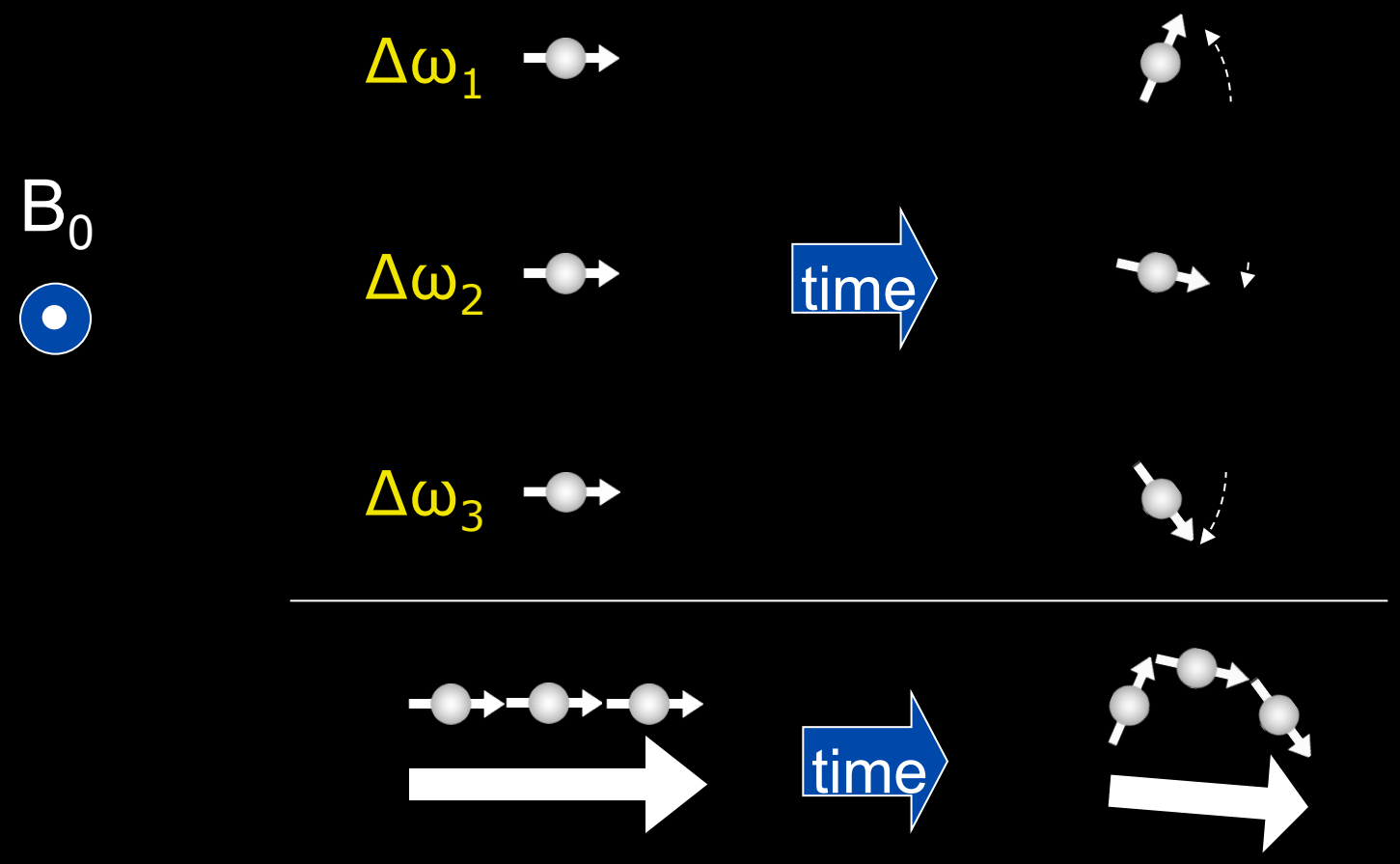

Net magnetization is reduced over time by varying precession rates

T_2 Relaxation

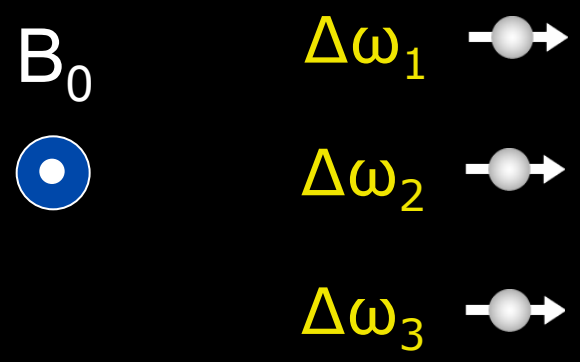

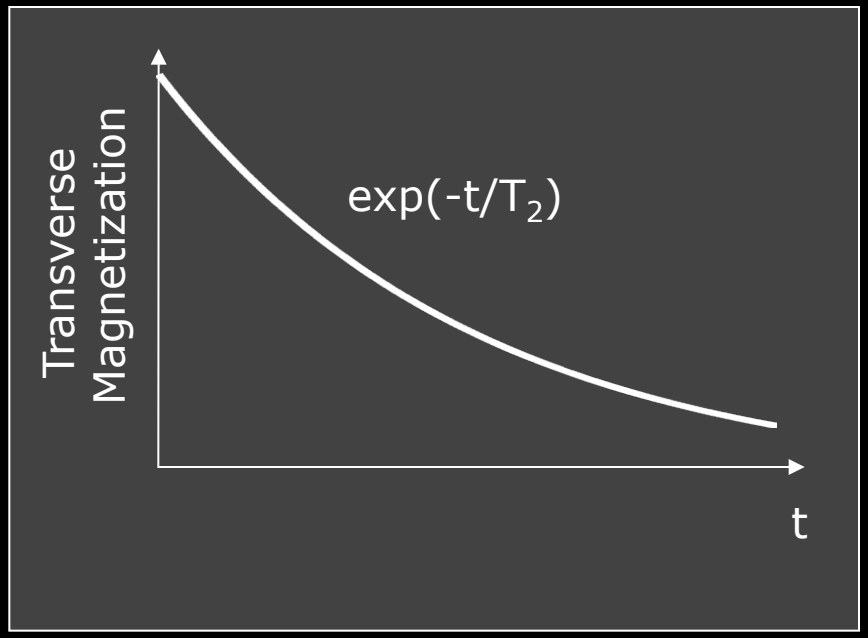

T_2 relaxation is caused by local field shifts from dipolar coupling

→ Dephasing and reductions of the transverse magnetization (M_{XY})

T_2 for Mobile Spins

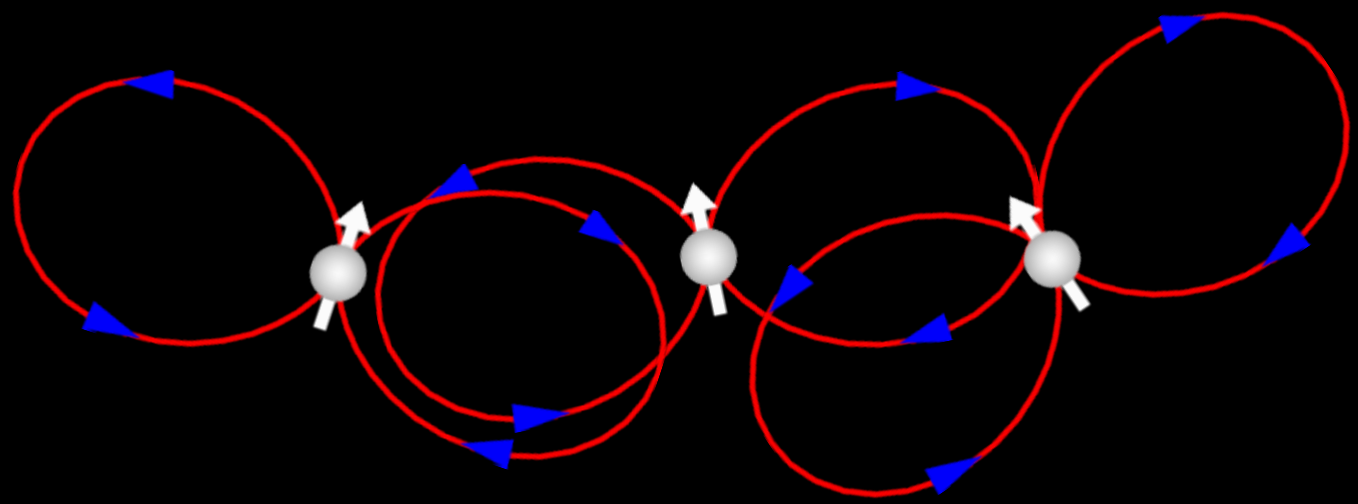

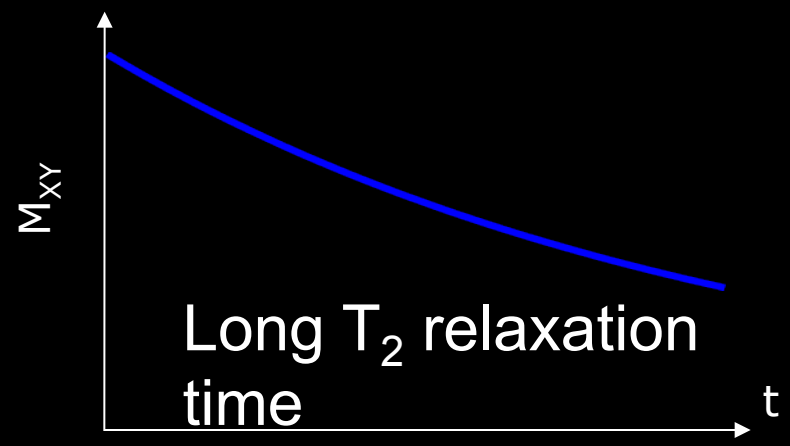

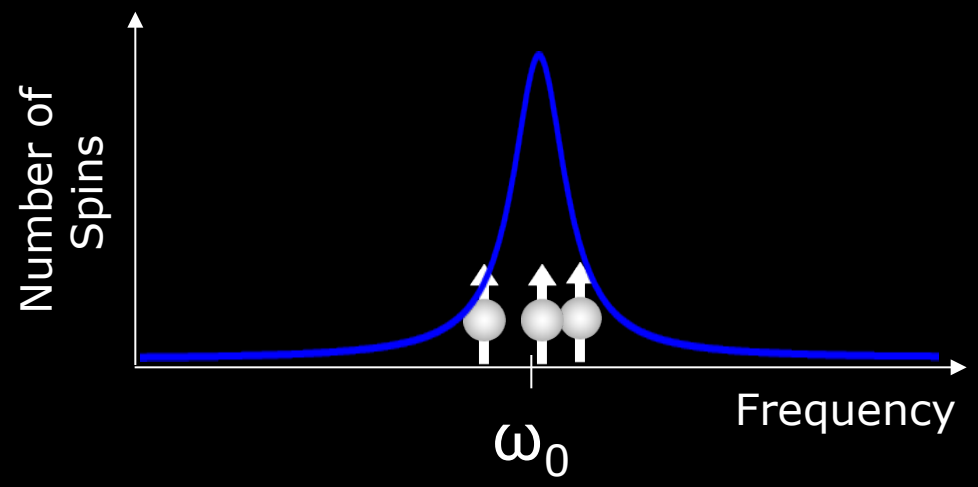

T_2 for Spins in Solids

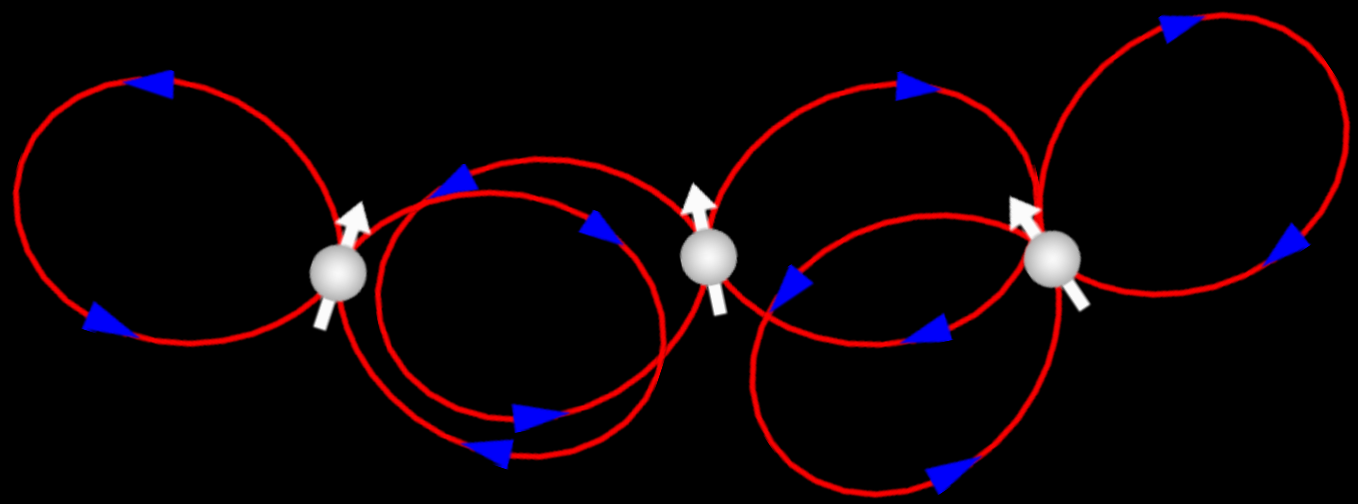

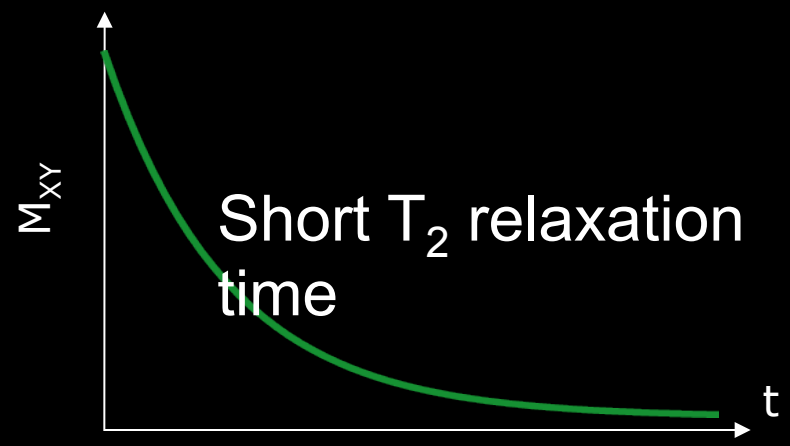

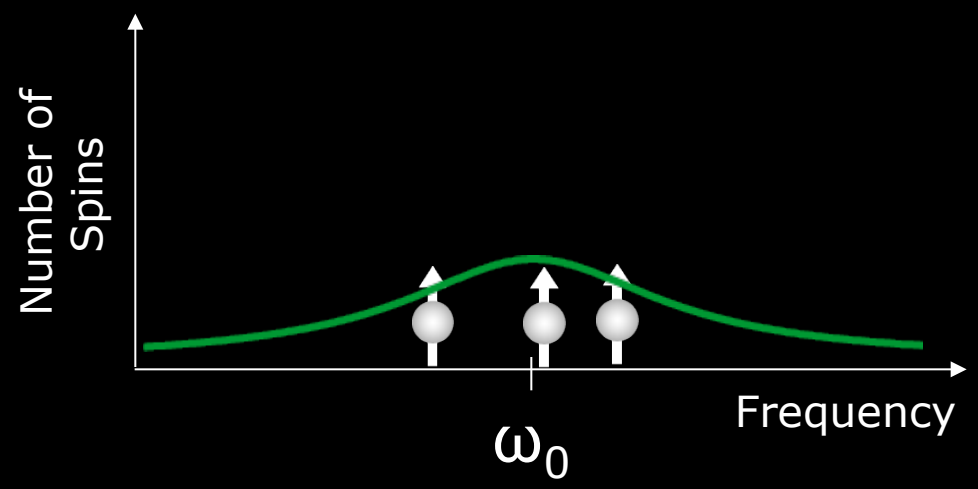

2D Ultrashort TE Pulse Sequence

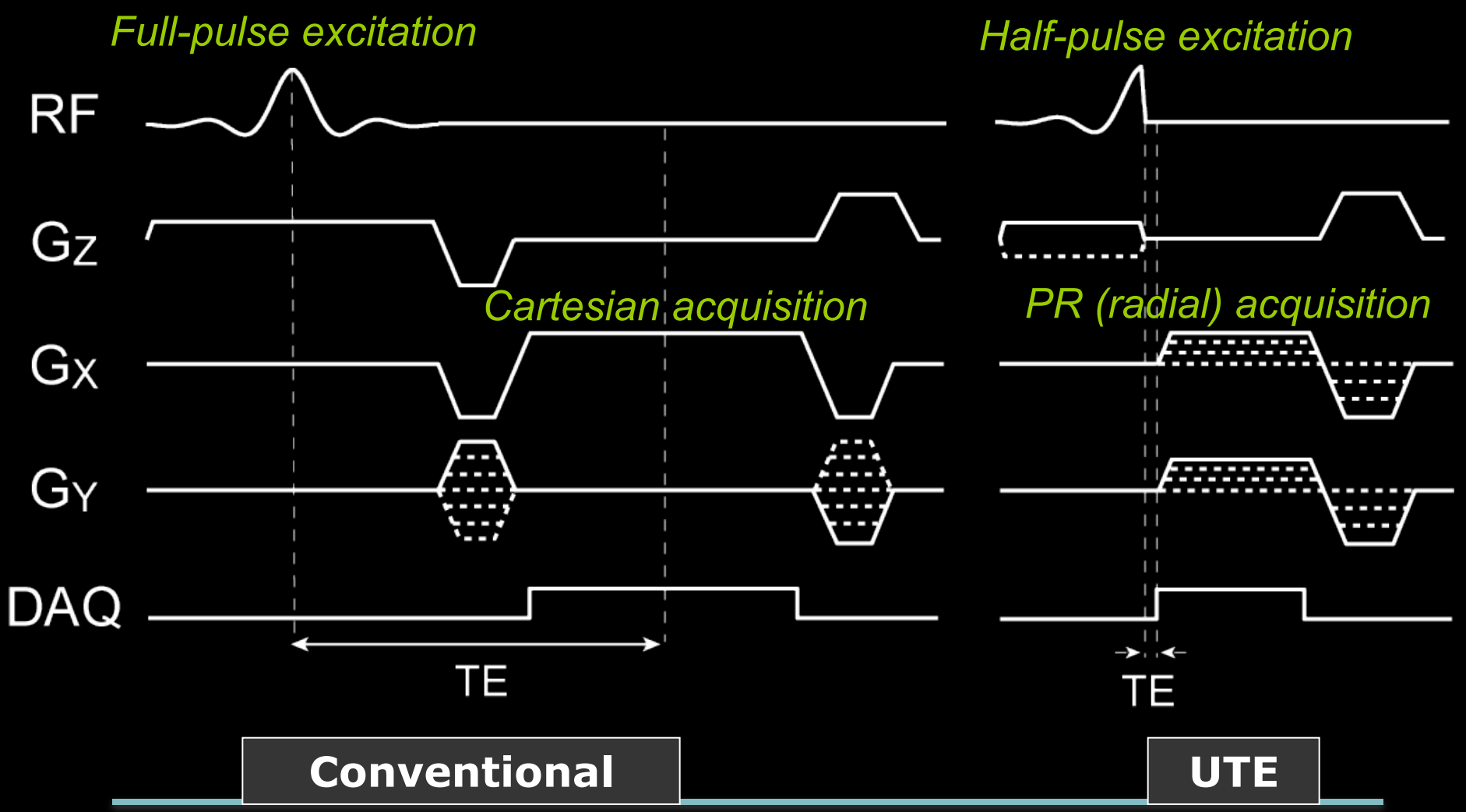

Conventional Excitation

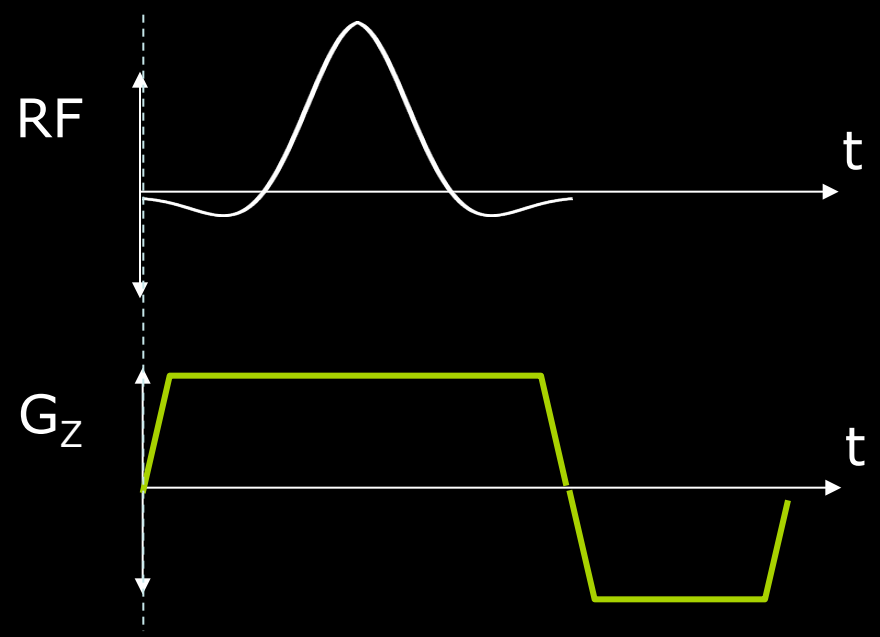

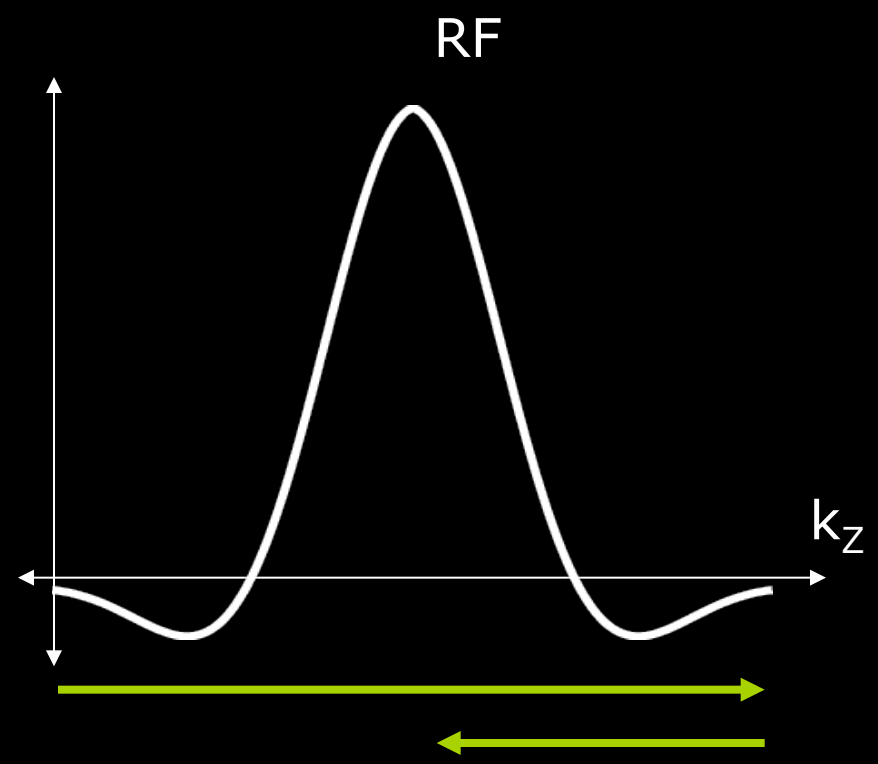

$k_Z = 0$

Always ends at center of excitation k-space

2D UTE Excitation

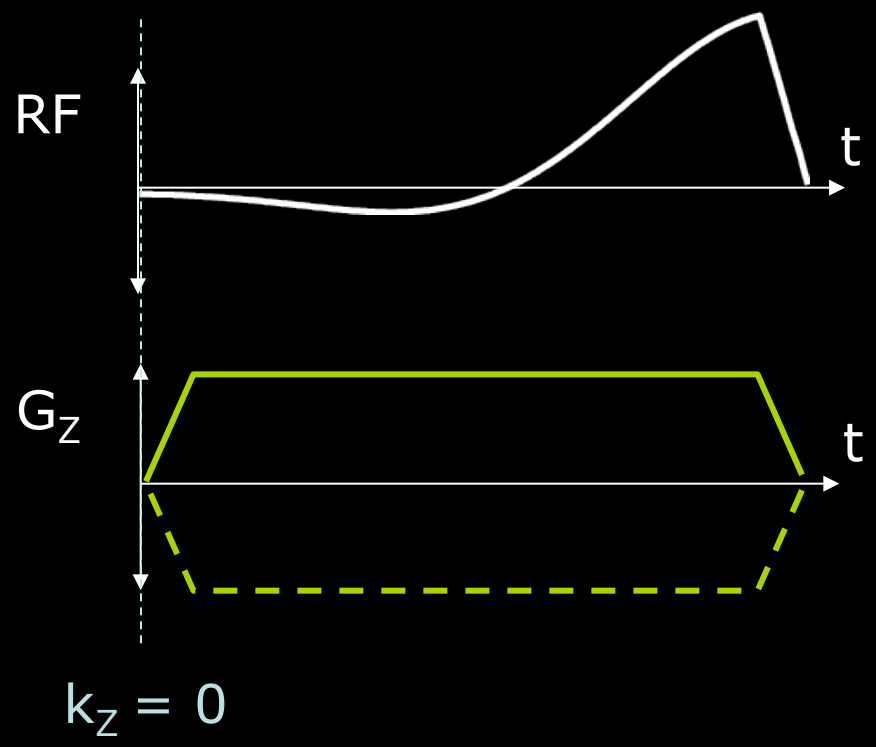

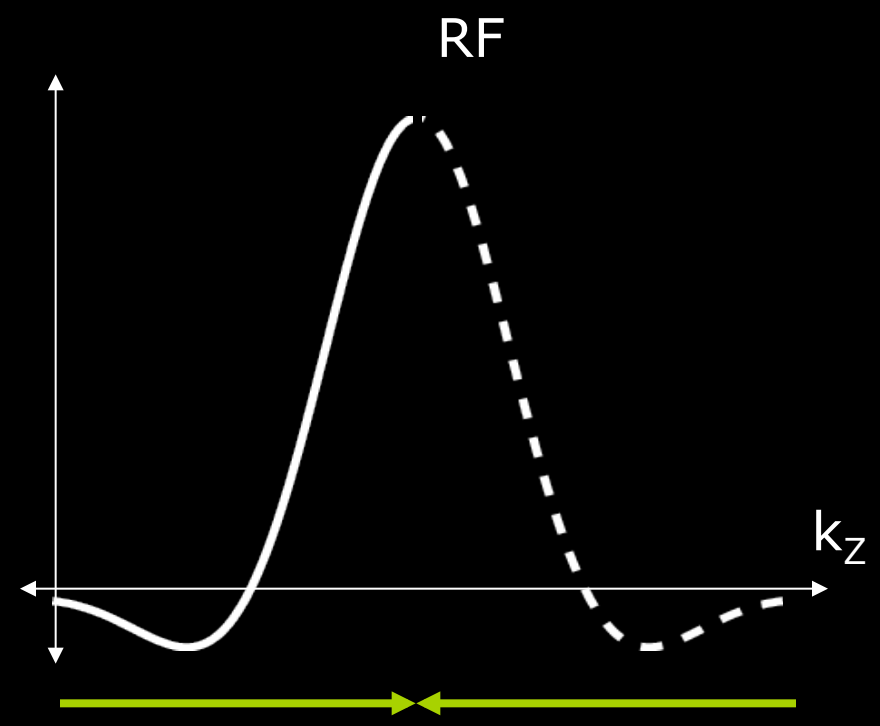

Half-pulses

Half-pulse Slice Profile

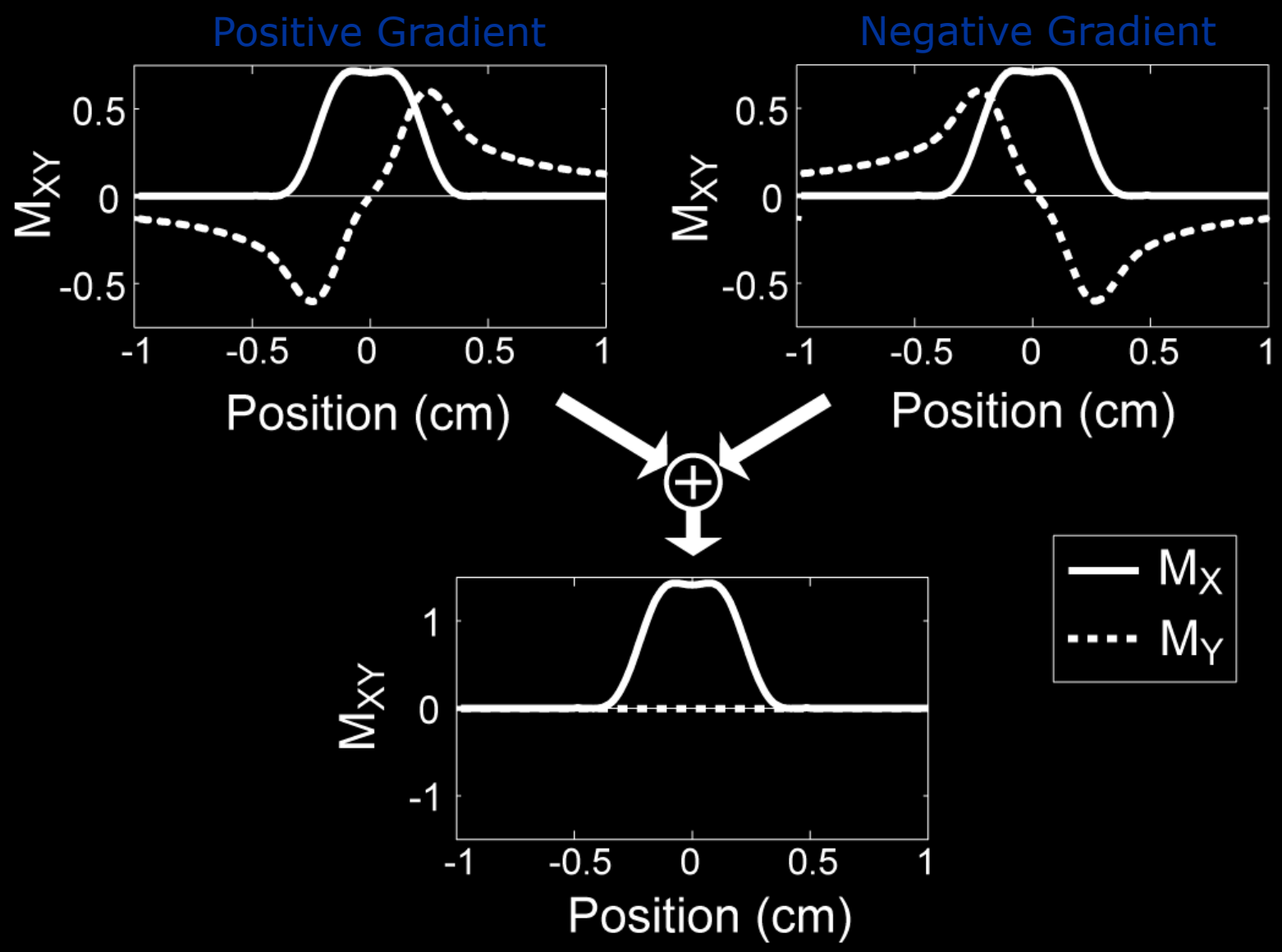

UTE Acquisitions

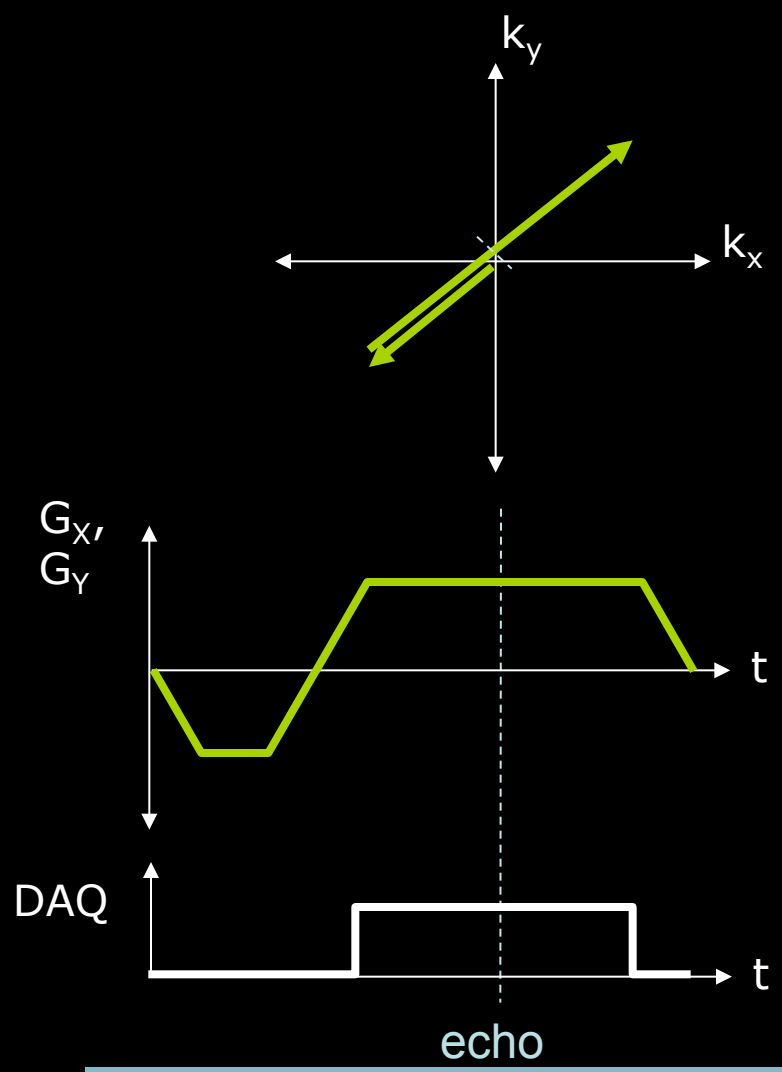

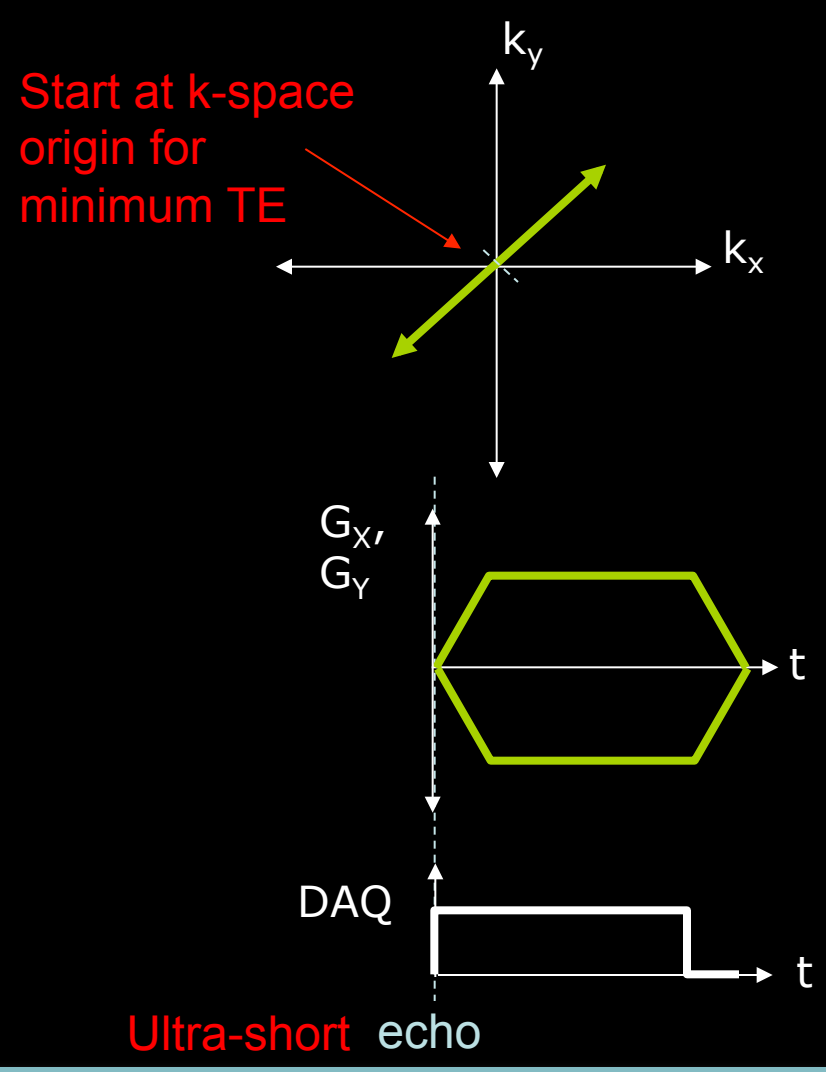

3D UTE Excitation

Hard Pulse

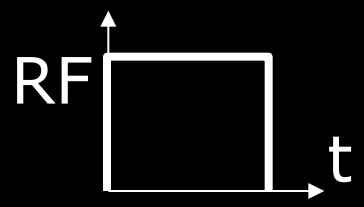

- Excites everything
- Short
- Minimum TE = 0

Minimum-phase Slab Pulse

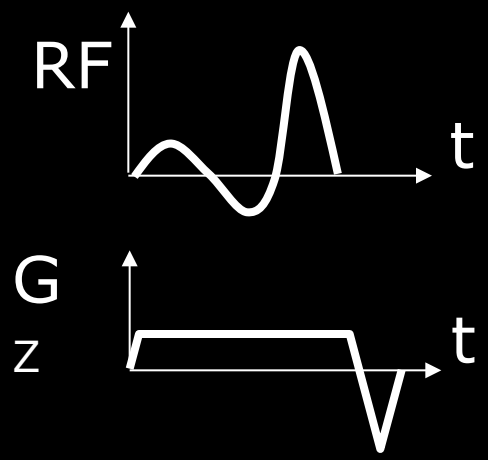

- Excites a slab
- Minimum TE and duration increased (~100 μs)
- Limits FOV and artifacts (gradient non-linearity)

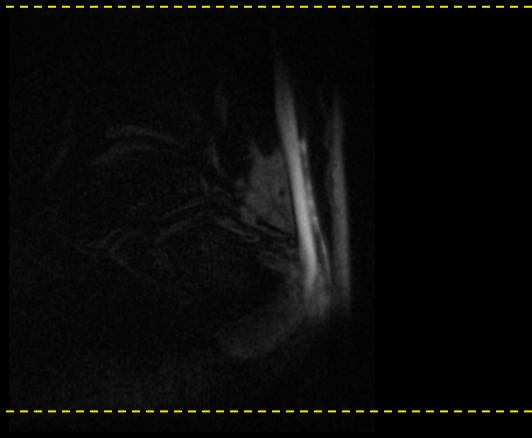

Images courtesy of Paul Gurney

3D UTE Acquisition

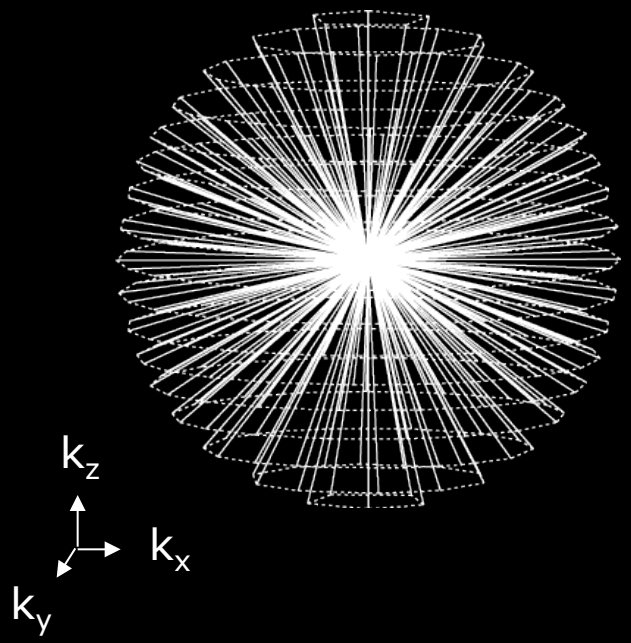

3D Radial Trajectory

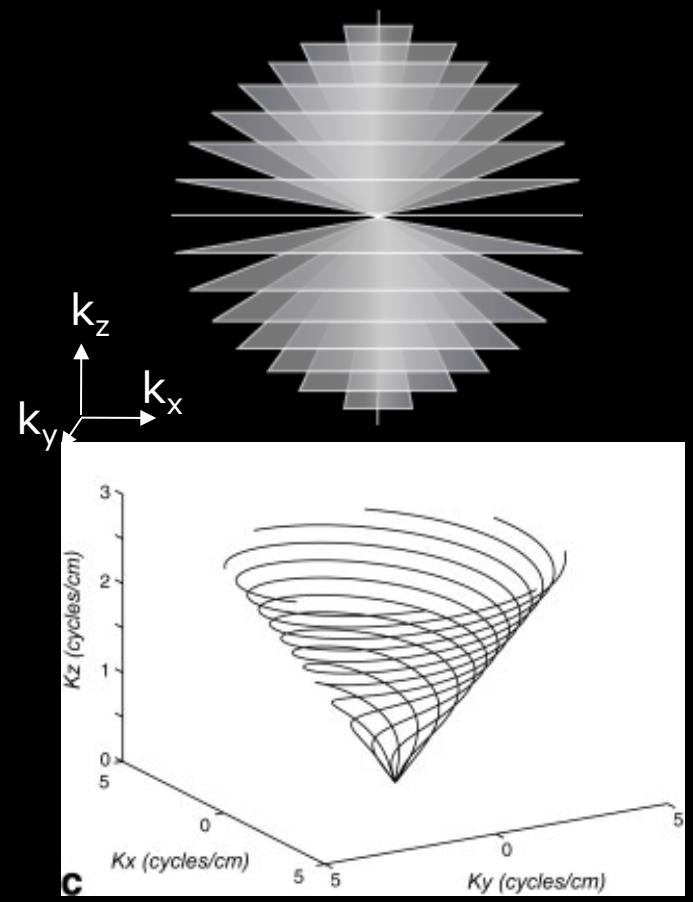

3D Cones Trajectory
Gurney et al. MRM 2006.

T_2 Slice Profiles

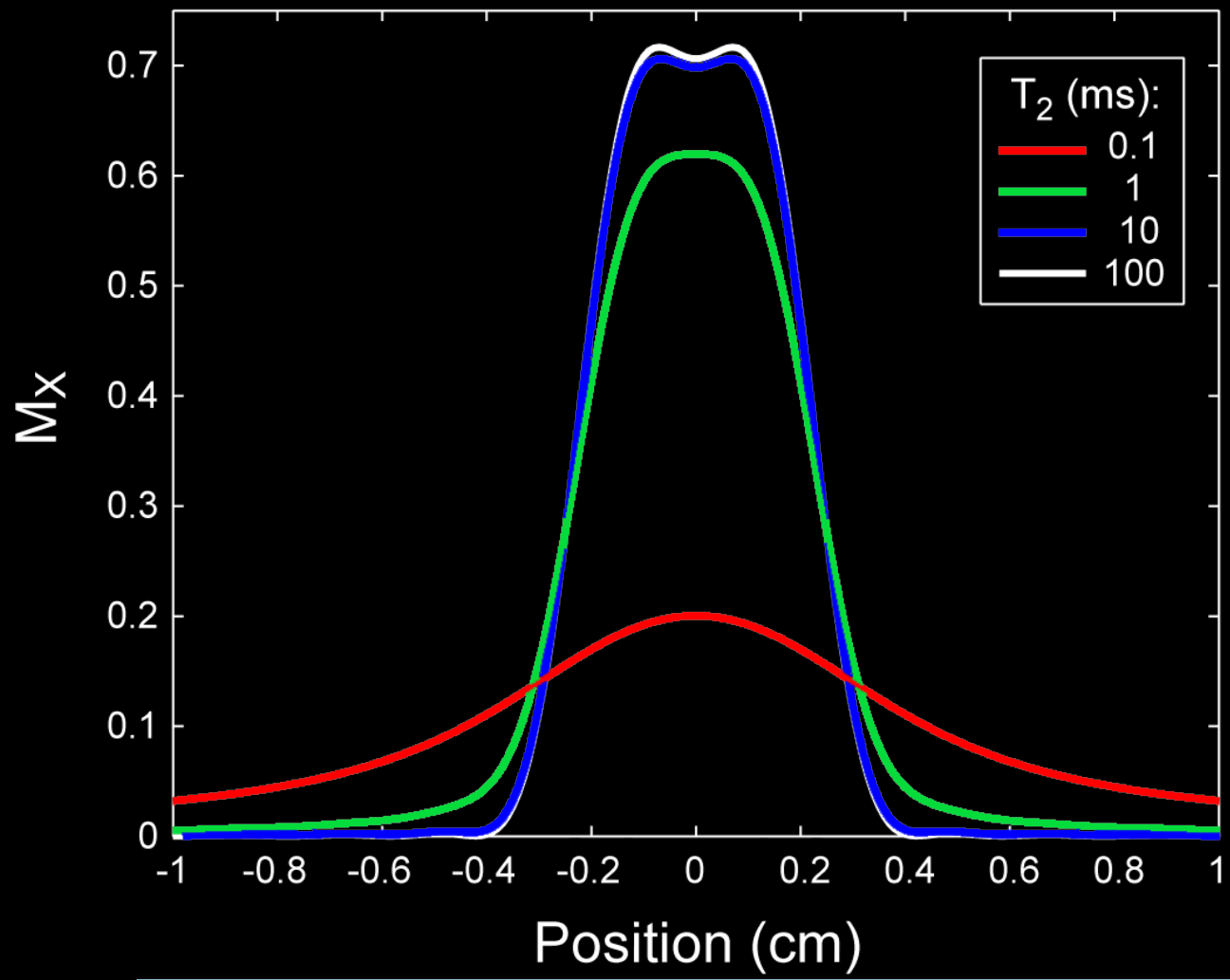

Slice profile blurs as T_2 decreases and as RF duration increases

T_2 Decay during Acquisition

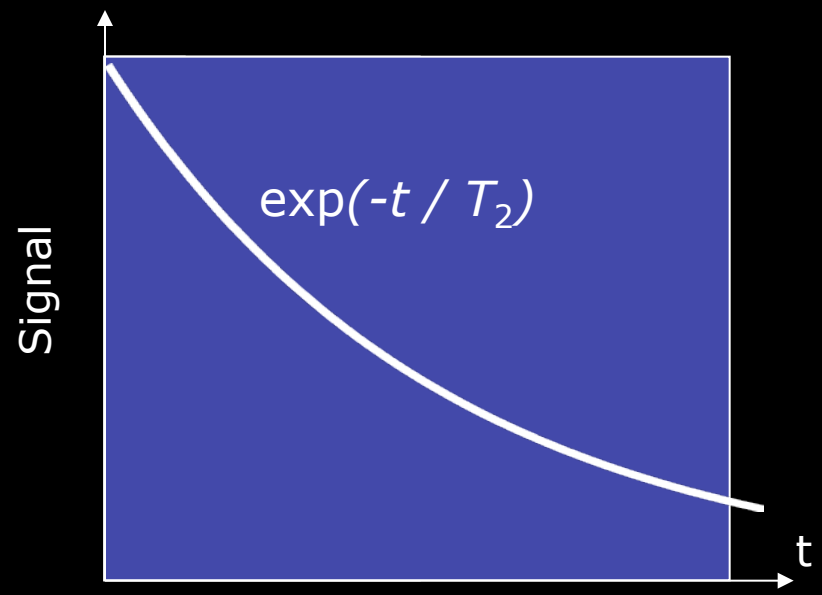

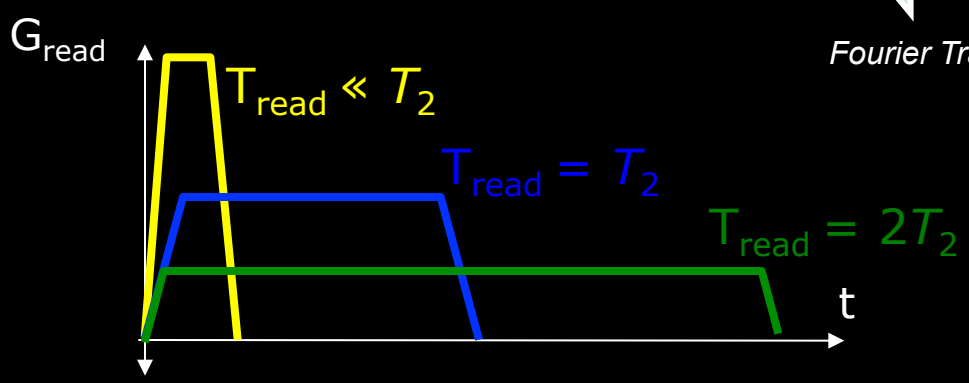

Fourier Transform

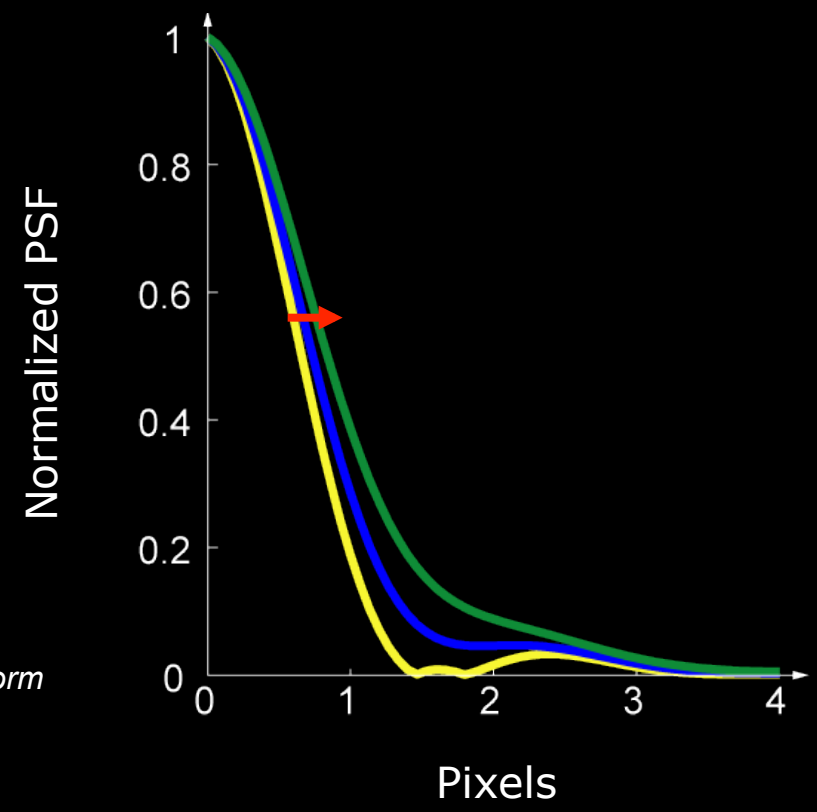

- Lose Resolution with T2 decay
- Tread « *T2* requires massive gradients and lowers SNR (sqrt(Tread))
- Use Tread ≈ T2 for optimal SNR

Varying TE Ankle Images

3D UTE image, TE=229 µs

TE=2.2 ms

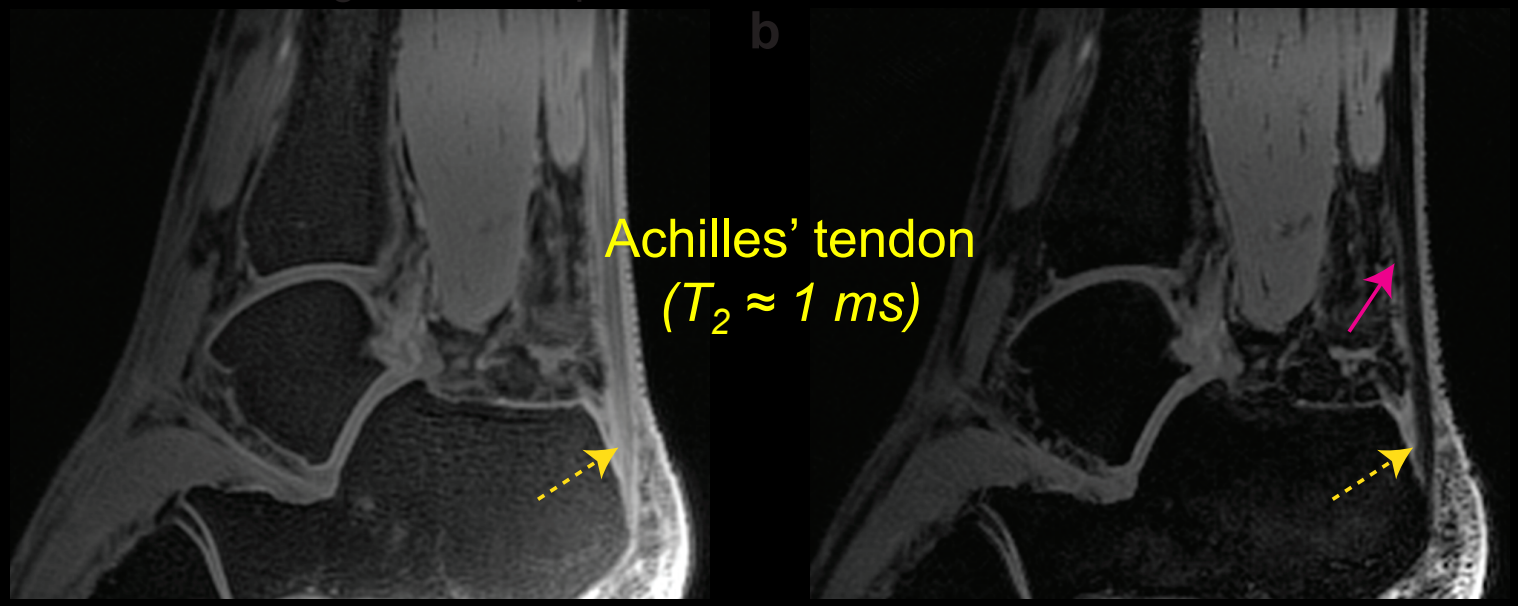

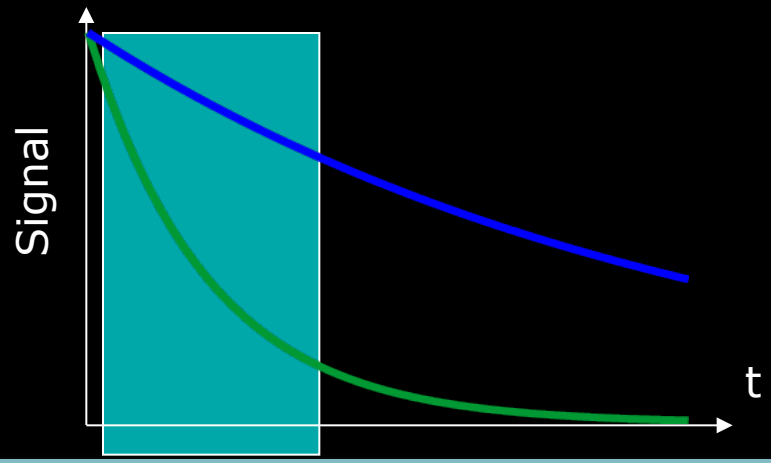

TE = 226 µs

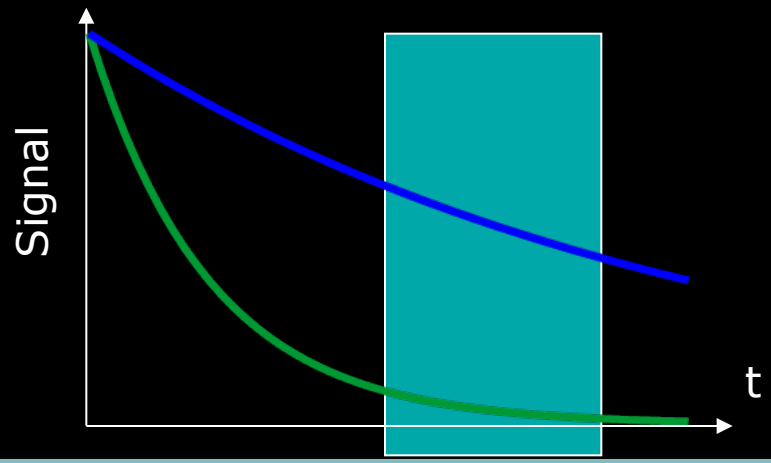

TE = 2.2 ms

Problem with UTE Imaging

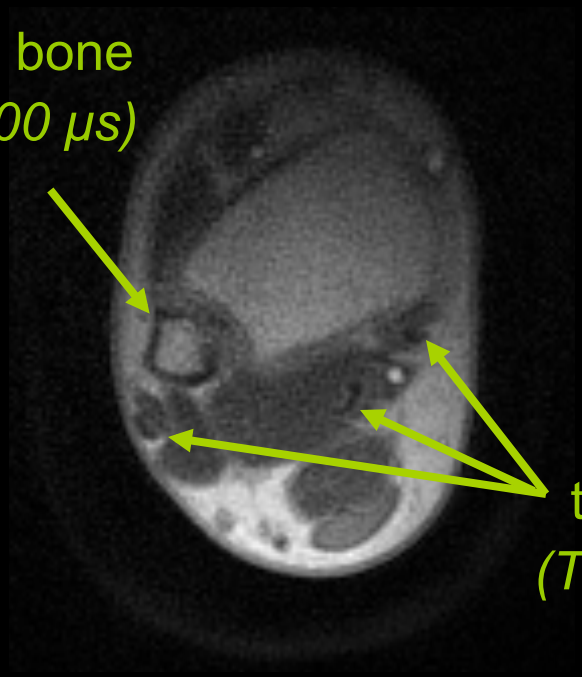

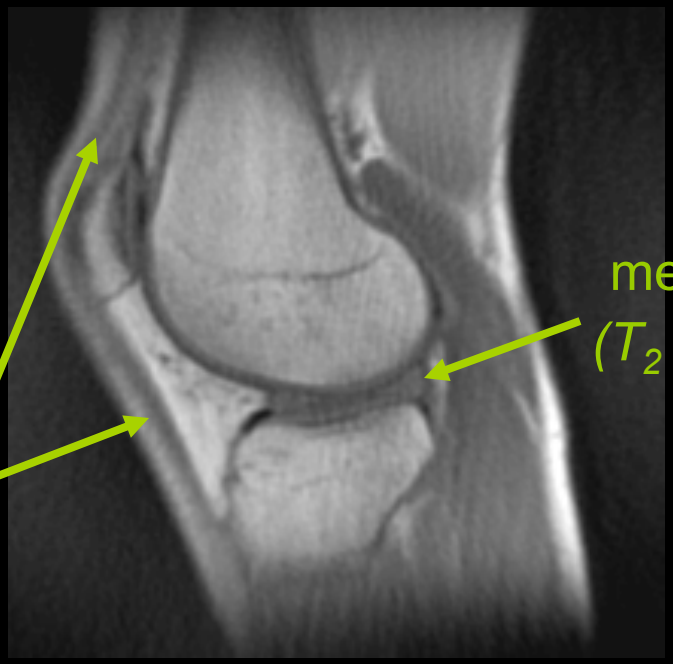

Poor short-T_2 component contrast
Signal from all tissues

Long-T_2 Suppression

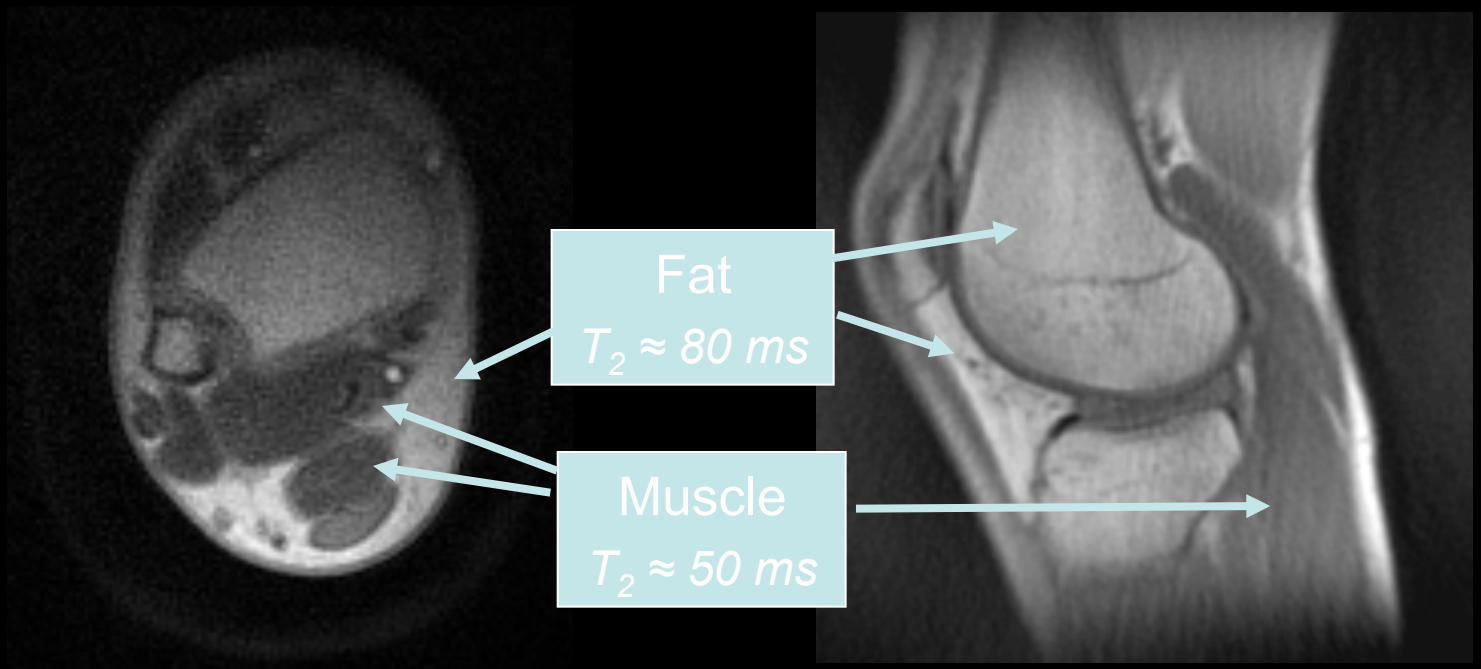

RF Pulse T_2 Contrast

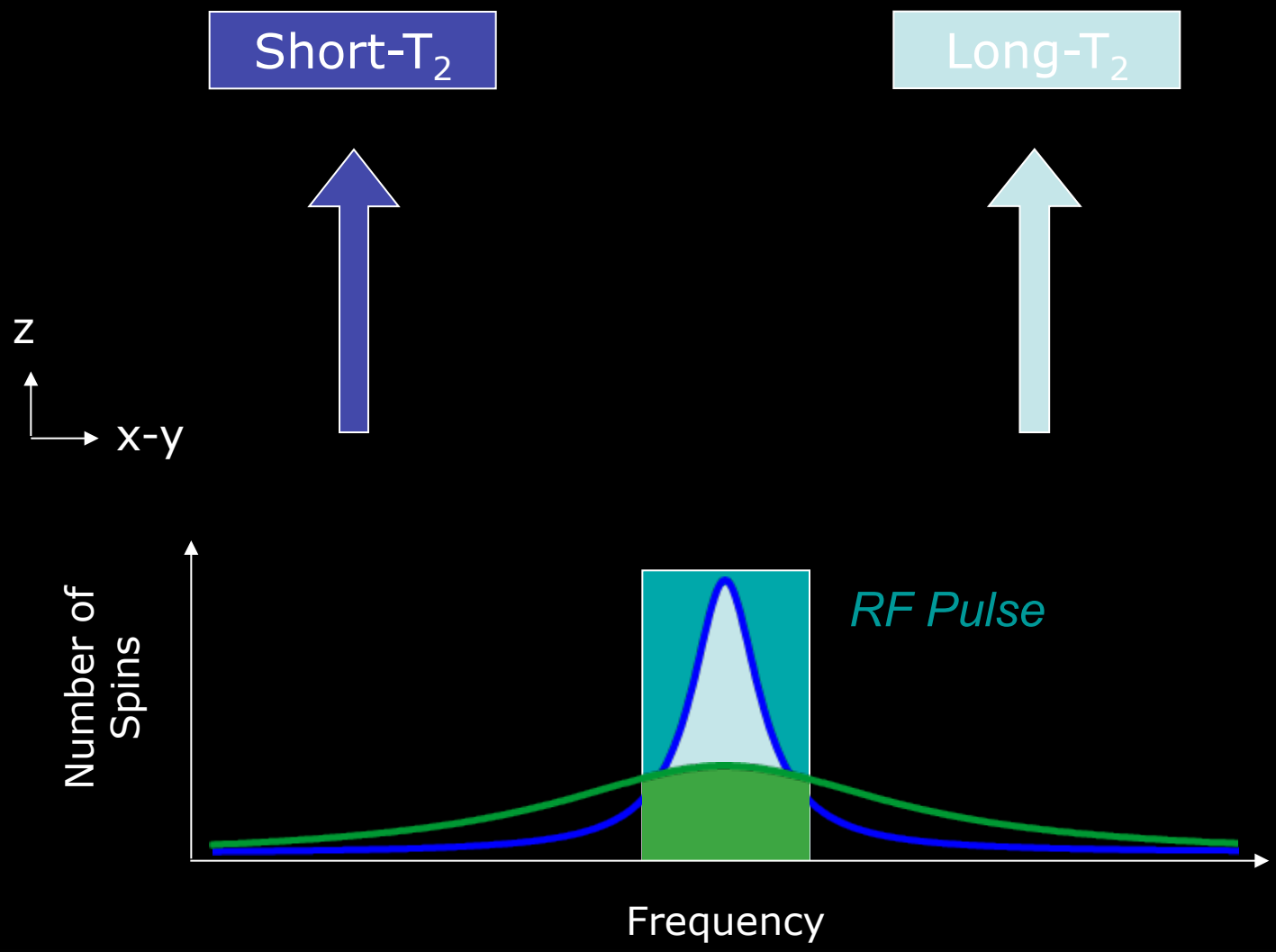

RF Pulse T_2 Contrast

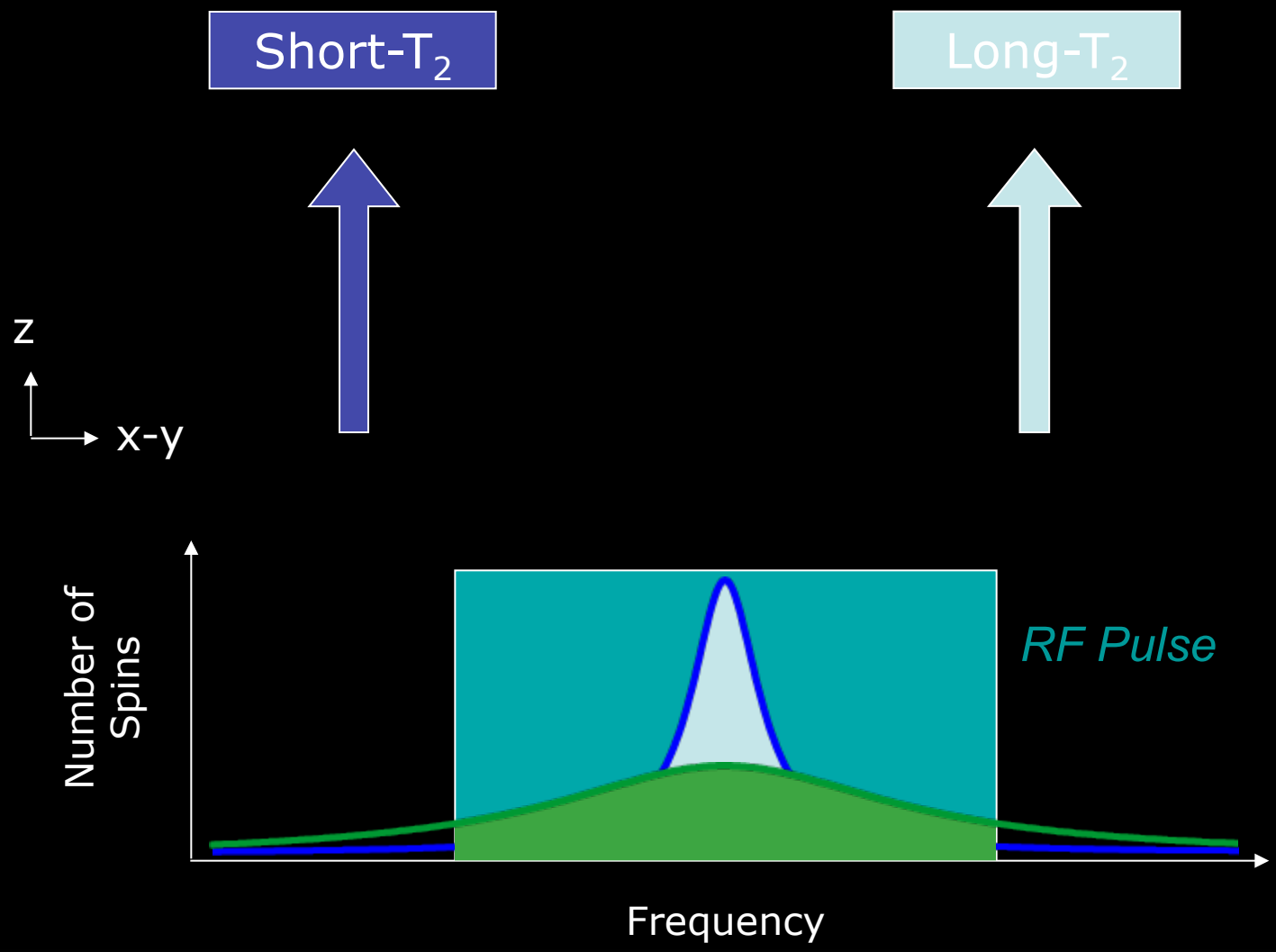

Long-T_2 Suppression Pulses

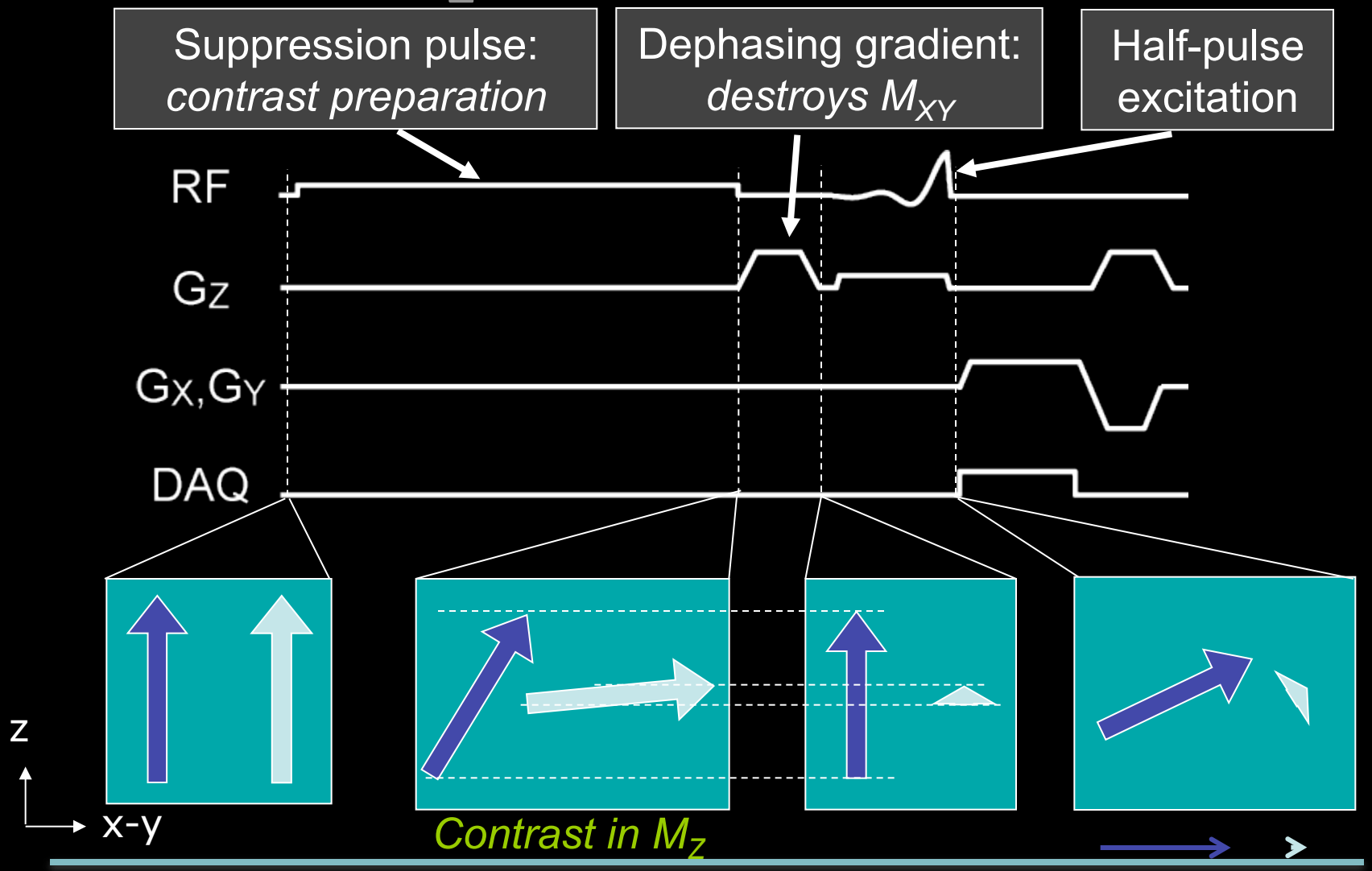

Improved Suppression Pulses

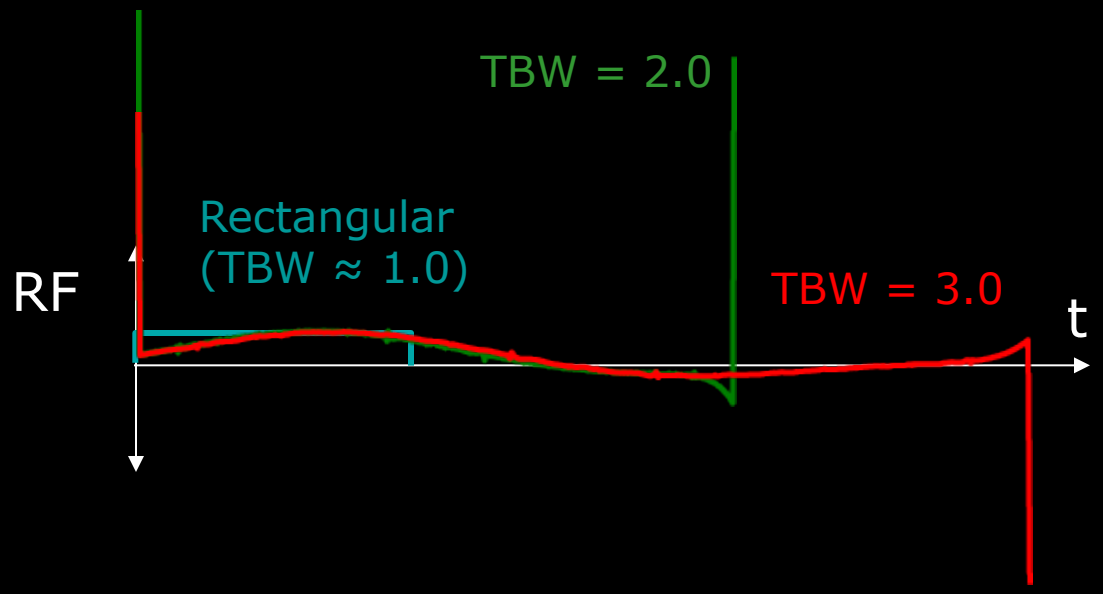

- Designed with Shinnar-Le Roux (SLR) Transform (*Pauly JM et al. IEEE-TMI 10:53-65 (1991).*)
- Precisely match desired spectral profile
- Time-bandwidth (TBW) - controls sharpness of profile

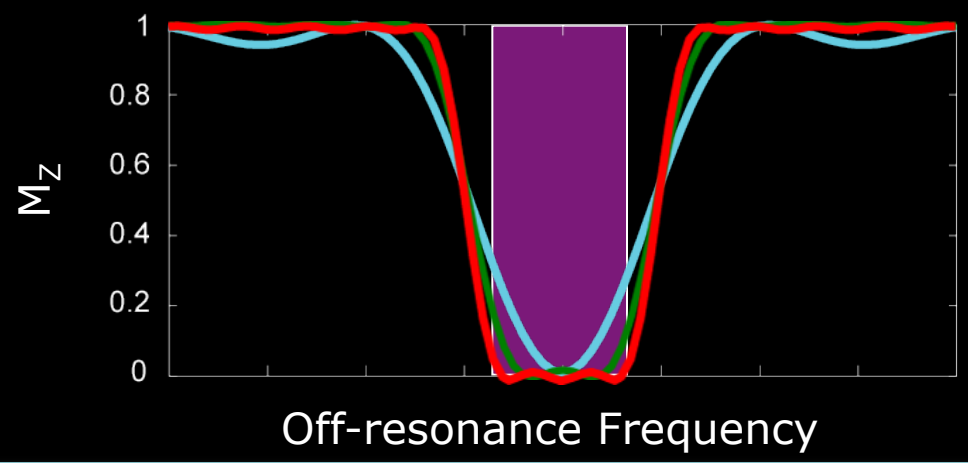

Suppression Results

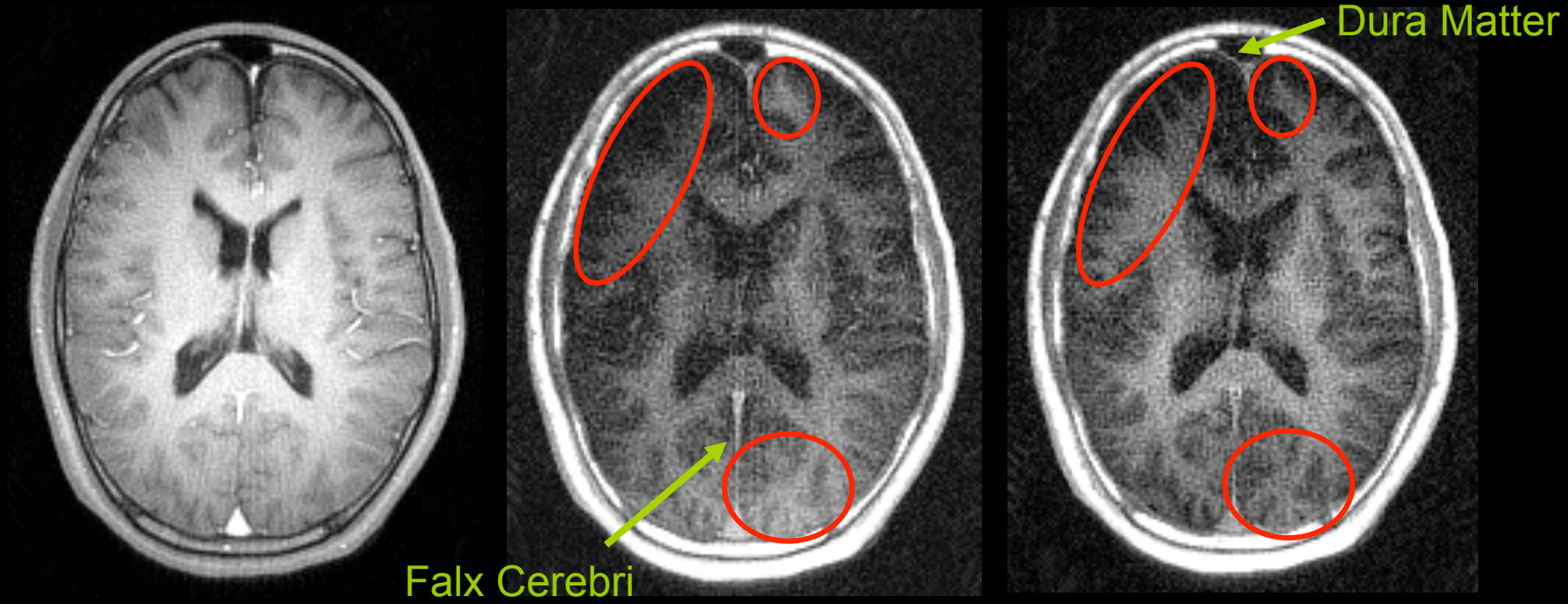

No Suppression

Rectangular Suppression Pulse

SLR-designed Suppression Pulse

TE = 80 us, TR = 500 ms, flip = 60 degrees, 5 mm slice thickness, 1 mm in-plane resolution, transmit/receive head coil, 1.5T GE Scanner ***4:15 min acquisition***

Rectangular pulse failures

Consistent white matter contrast *(likely Myelin)*

Adding Fat Suppression

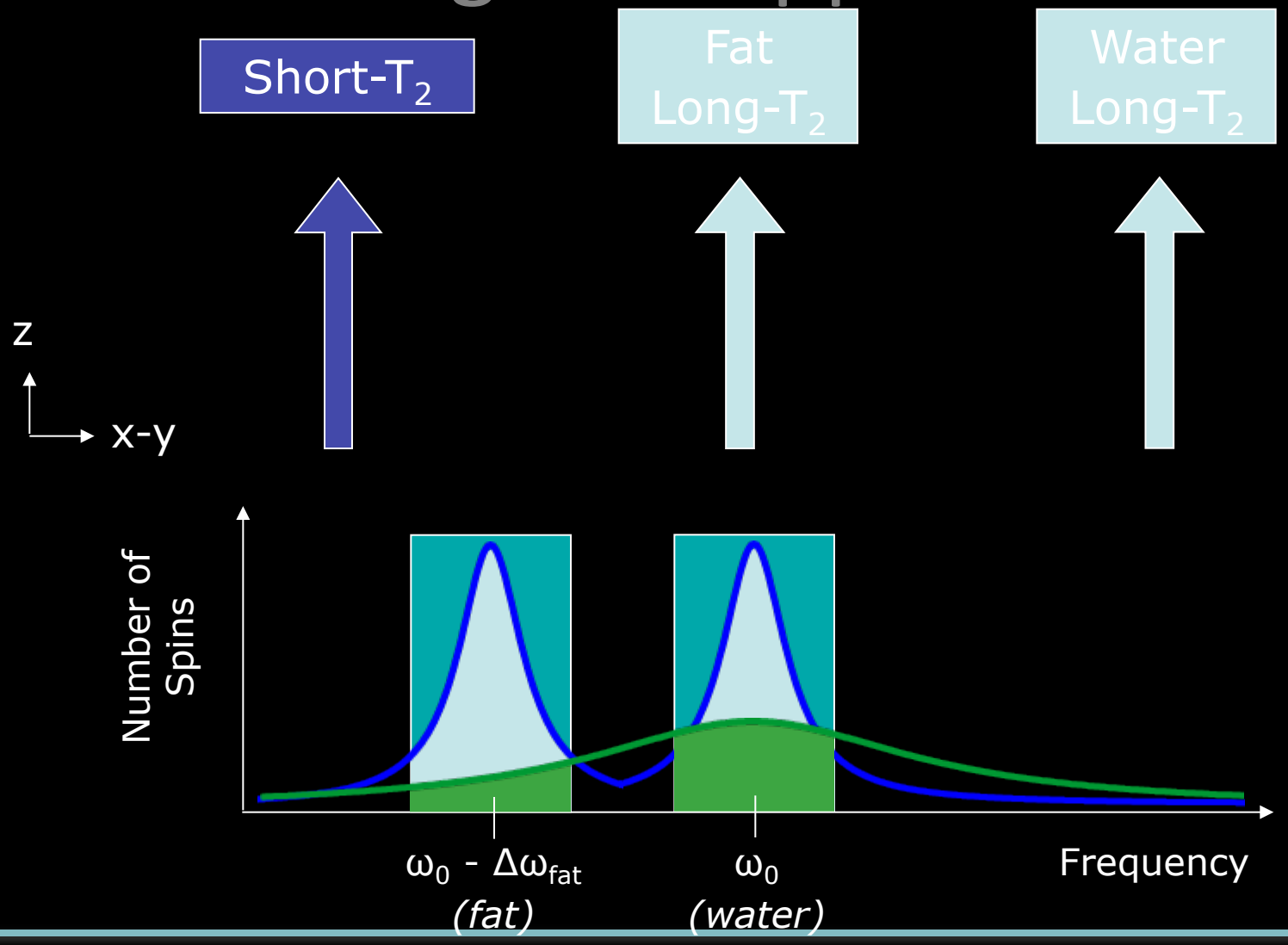

Dual-Band Suppression Pulses

Using SLR pulse design

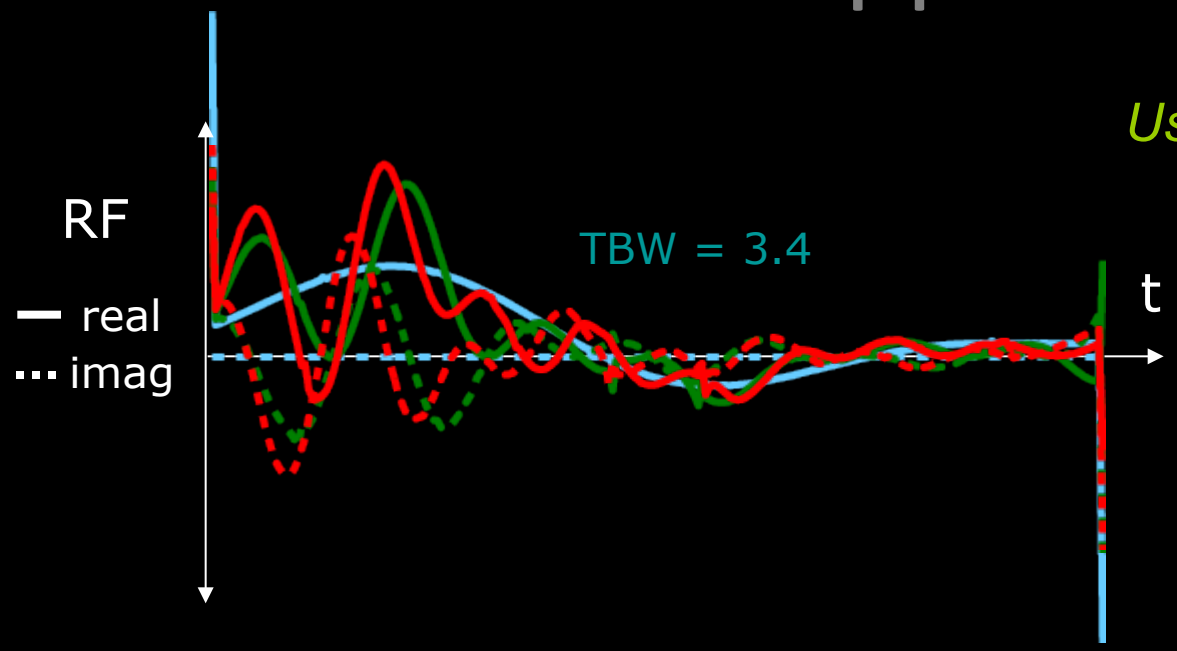

+ Fat suppression band
- Additional short-T_2 signal loss

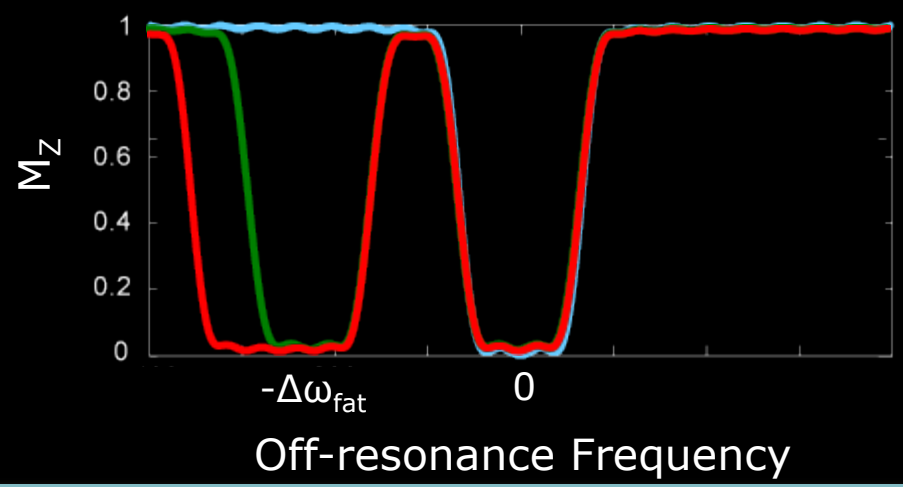

3D Ankle Images (1.5T, 2005)

No Suppression

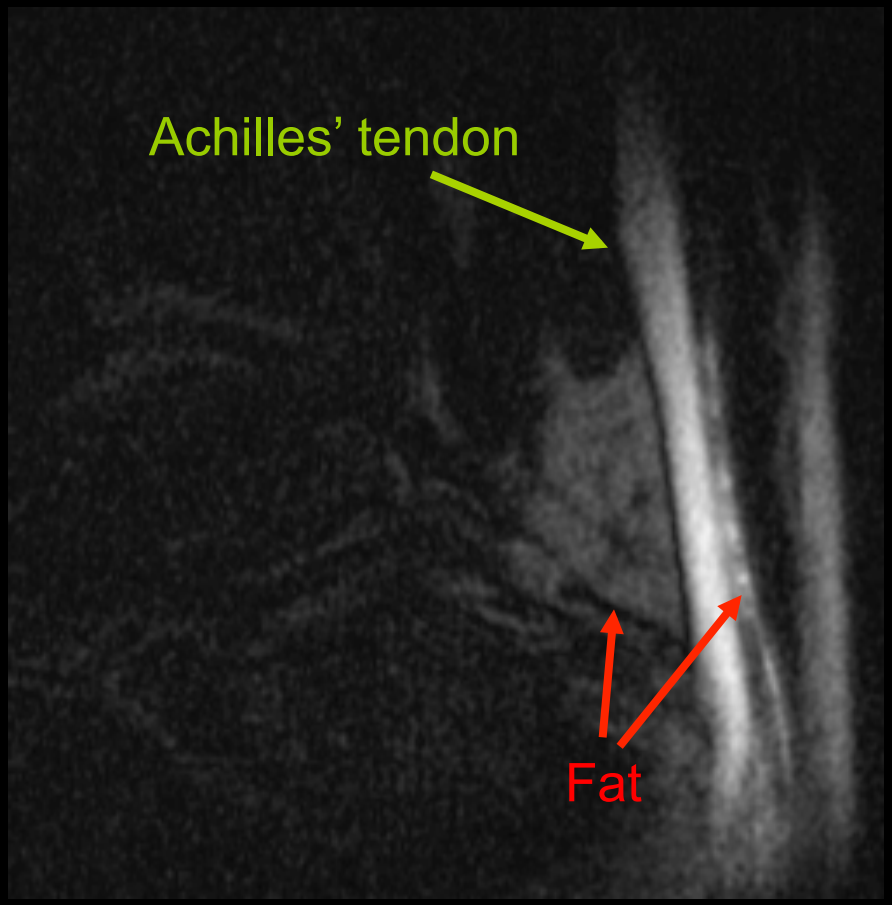

Dual-band Long-T_2 Suppression Pulse

3D Ankle Images (1.5T, 2005)

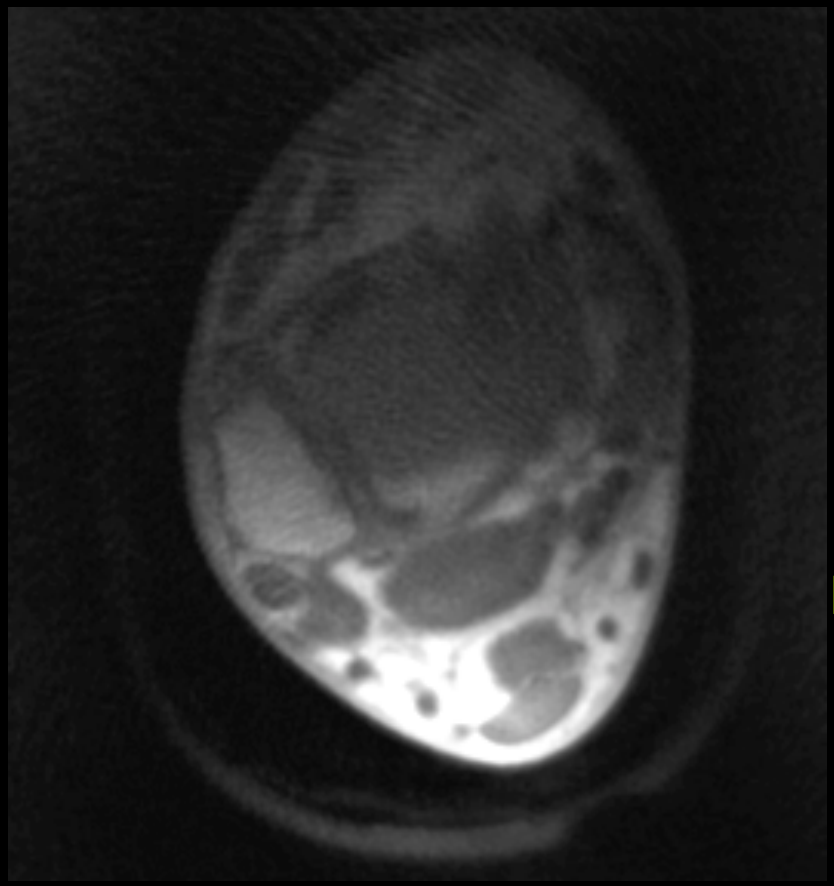

No Suppression

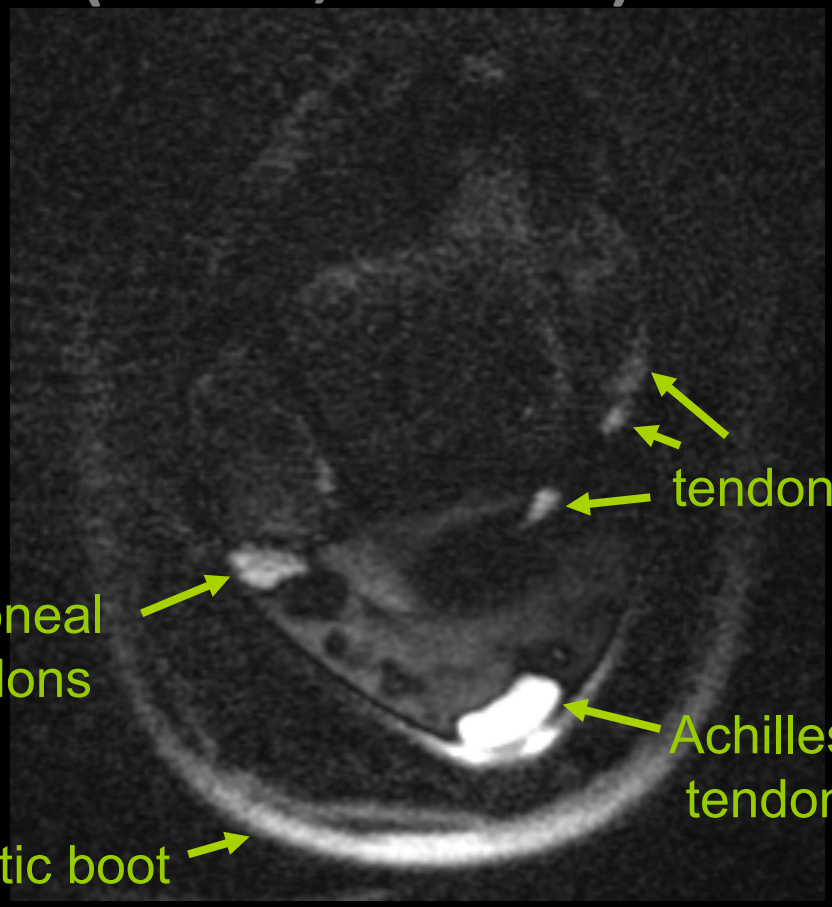

Dual-band Long-T_2 Suppression Pulse

3D Ankle Images (7T, 2014)

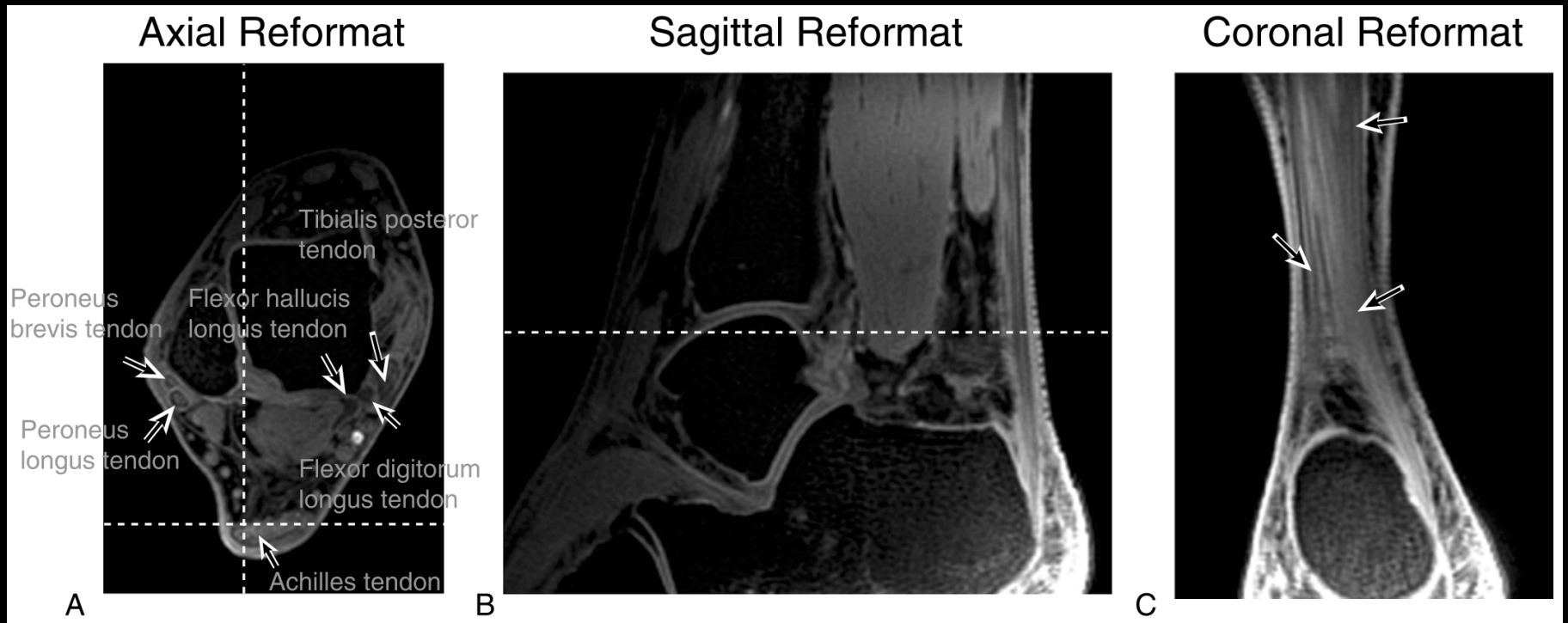

FIGURE 5. Internal structural analysis of the Achilles tendon. A to C, Axial, sagittal, and coronal reformatted slices. The positions of the slices are denoted as dashed lines in A to B. A fascicular pattern is observed in the tendon. C, The orientations of the fascicles can be characterized, allowing for distinguishing different groups of fascicles as denoted by arrows. Numerous other tendons in the ankle are also well depicted, indicated in A.

Han et al. Inv Radiology, 2014.

UTE Lung Imaging

1.25mm resolution, Resolved over 5 respiratory phases

Jiang et al. Proc ISMRM 2016.

UTE Lung Imaging

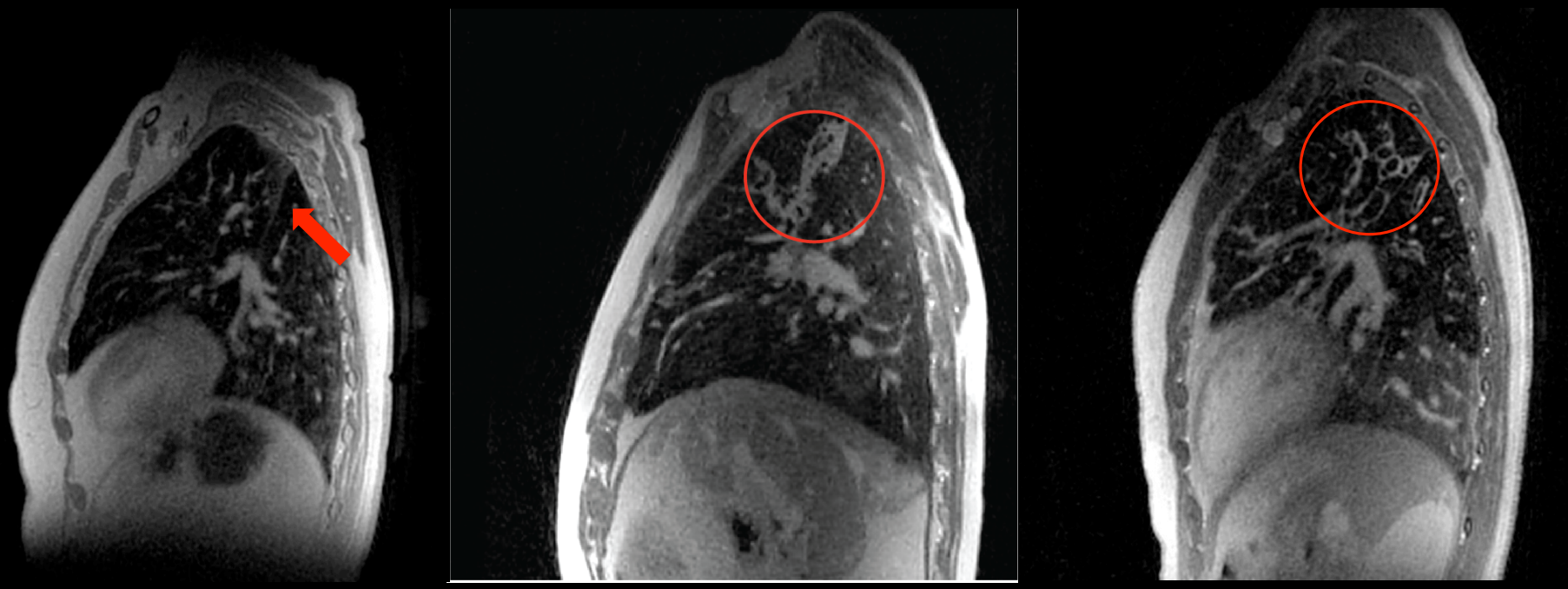

Jiang et al. Proc ISMRM 2016.

Zero Echo Time (ZTE) MRI

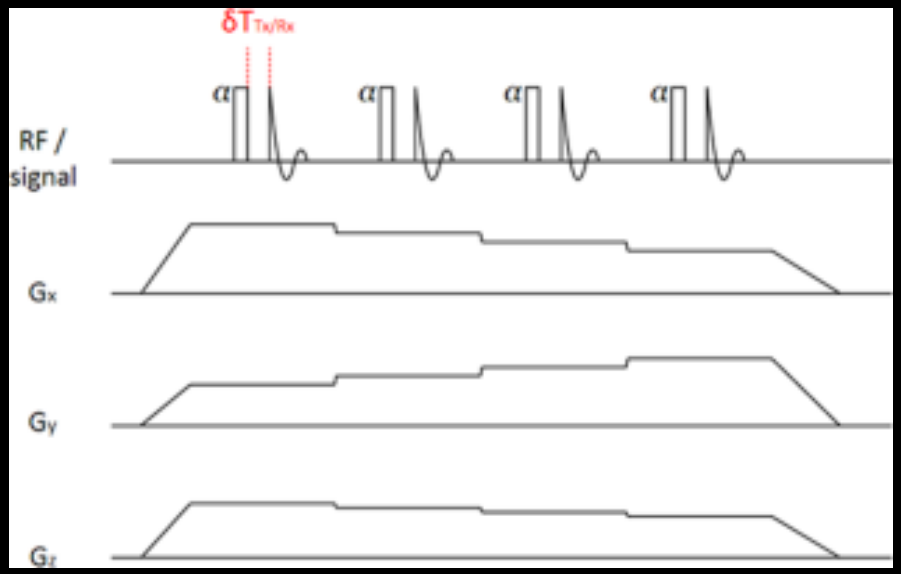

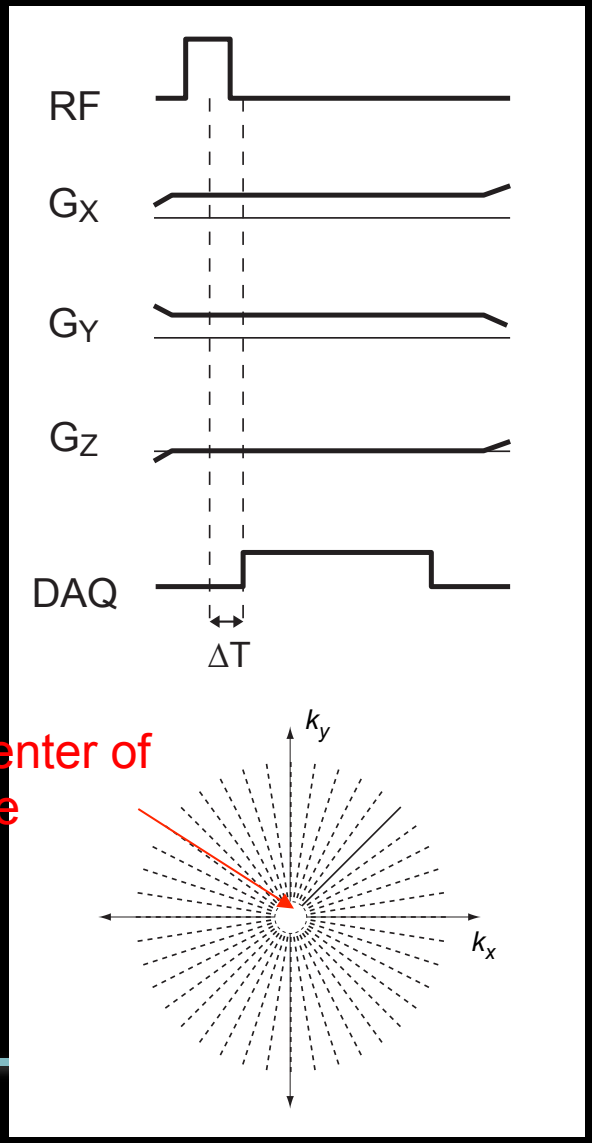

- Zero echo time: cross center of k-space during RF pulse
- But don't acquire center of k-space
  - Algebraic reconstruction
  - Fill in with single point acquisitions
  - Fill in with low-resolution projections

Zero Echo Time (ZTE) MRI

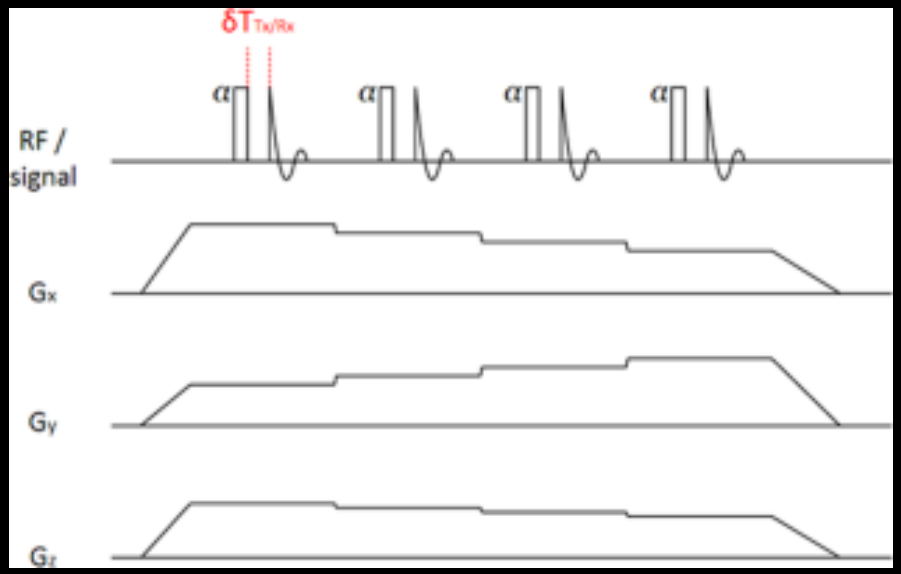

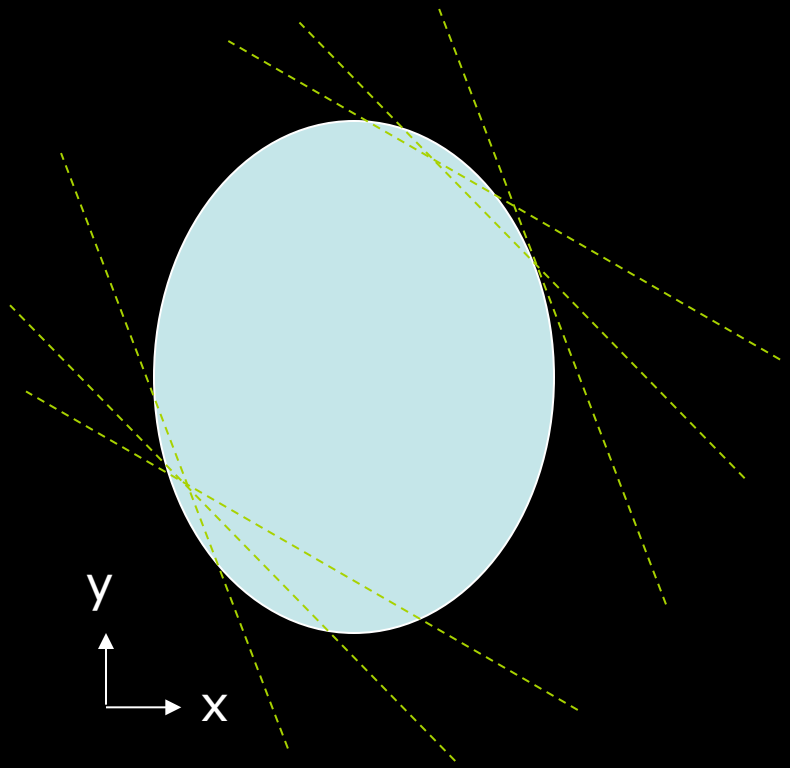

- Silent scan due to slow ramping of gradients
- Limited flip angle and volumetric coverage due to “slice selection” during RF pulse
- “Slice” changes every TR! Blurring artifacts

ZTE Bone Imaging

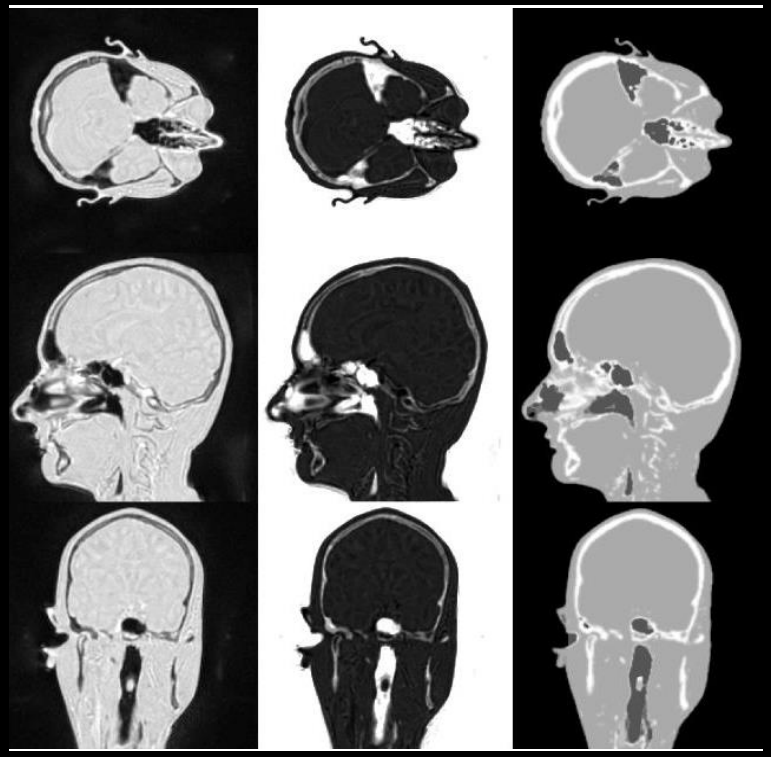

ZTE Bone

Wiesinger, et al. MRM (2015). Delso, et al. J Nuc Med (2015). Leynes, et al. Proc ISMRM 2016.

ZTE Tendon Imaging

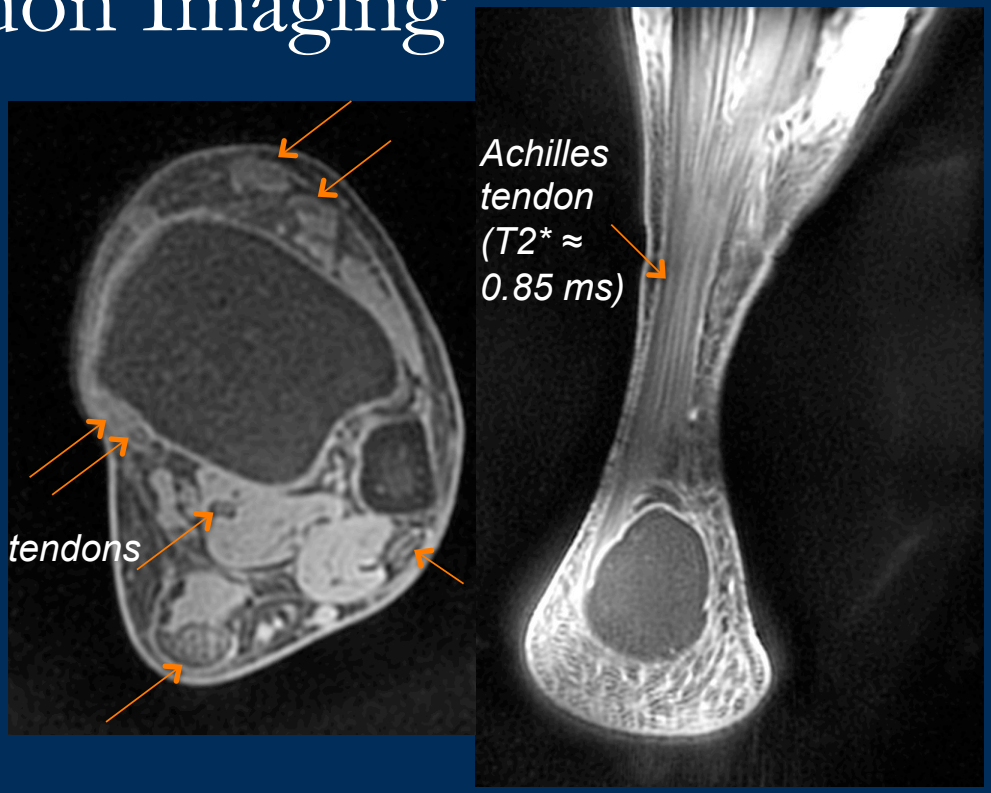

- Excellent tendon visualization, including fascicular structure of Achilles' tendon
- 0.7mm isotropic resolution
- 4:45 scan time

Larson et al. MAGMA 2015.

ZTE Knee Imaging

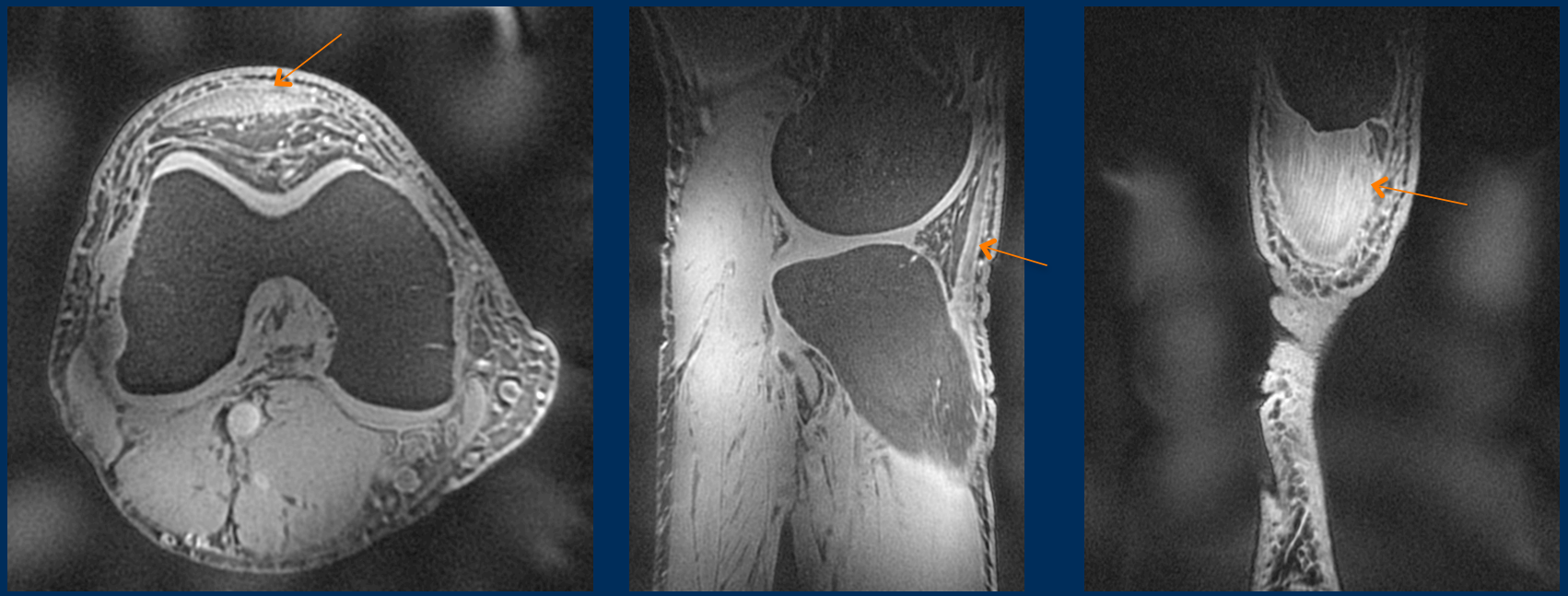

- Excellent tendon, ligament, cartilage, and meniscus visualization
- 0.6 mm isotropic resolution
- 4:45 scan time

Larson et al. MAGMA 2015.

UCSF

Other UTE Images

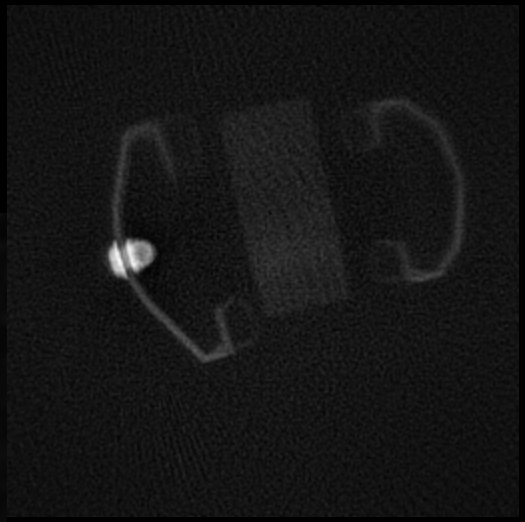

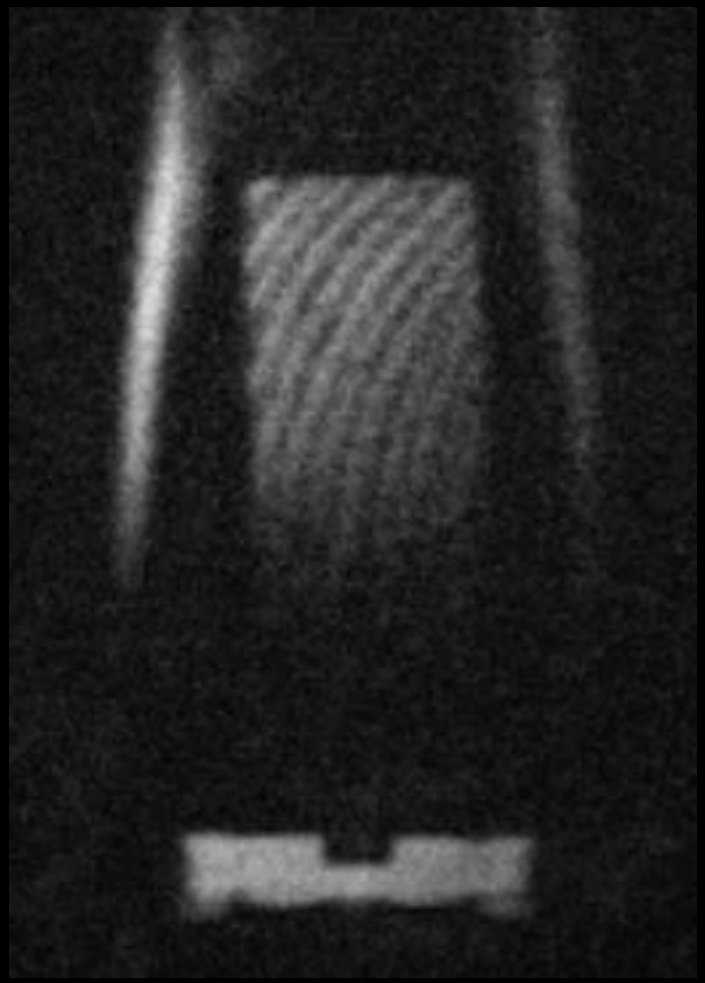

3D UTE Violin Images

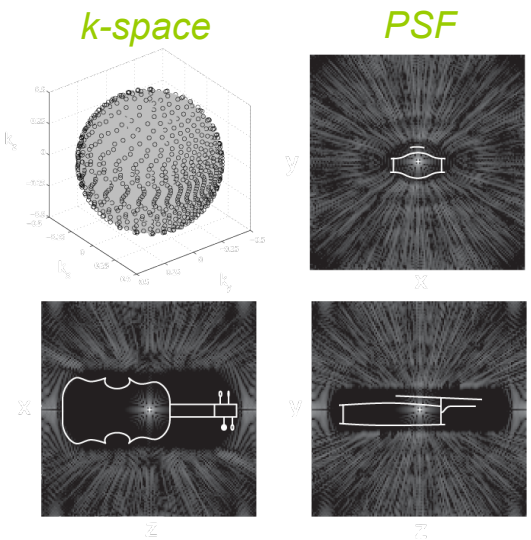

3D PR acquisition with FOV tailored to the violin shape
Larson et al. *IEEE Trans Med Imag* 2008; 27:47-57.

TE = 64 us, TR = 5.2 ms, 1.3-1.8 mm in-plane resolution, 3” surface coil, transmit/receive head coil, 1.5T GE Scanner
1 min 43 s and 19 min acquisition

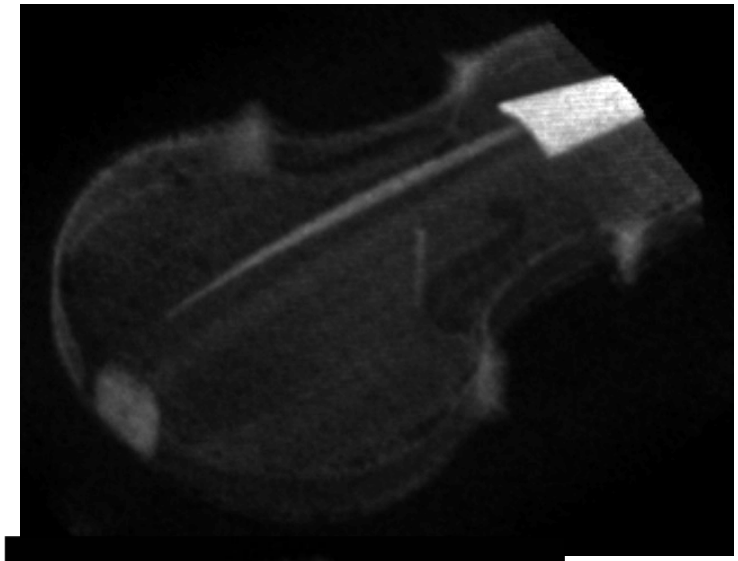

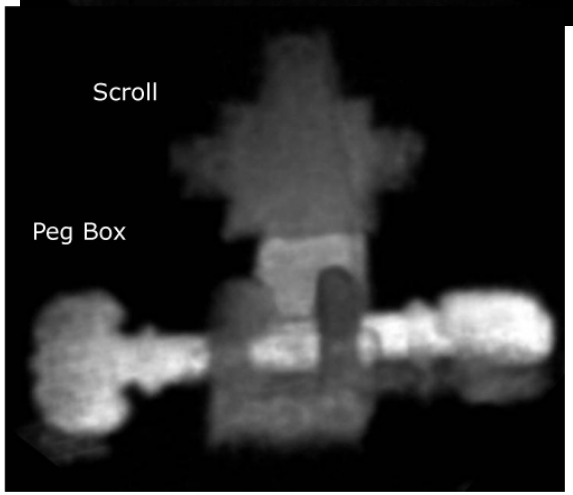

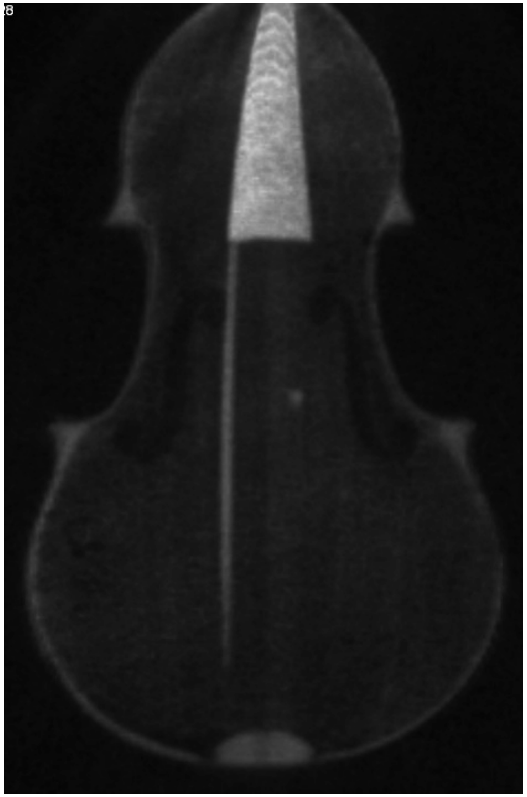



Barral et al. Proc 49th ENC 2008.